Cell therapy in Parkinson's disease

Dani Offen
Felsenstein Medical Research Center
Sackler School of Medicine, Sagol School of Neuroscience
Tel-Aviv University, Israel

The Felsenstein Medical Research Center

Norma and Alan Aufzein
Chair for Parkinson's Disease Research

Movement Disorders
Official Journal of the International Parkinson and Movement Disorder Society

EDITORIAL

Eldad Melamed 1942-2015: Ave Atque—A Memorial

C. Warren Olanow, MD, FRCPC[1]* and Werner Poewe, MD[2]

[1]Department of Neurology, Mount Sinai School of Medicine, New York, New York, USA
[2]Medical University Innsbruck, Innsbruck, Austria

Eldad Melamed died on October 1, 2015. Unknown to most of his countless friends and colleagues around the world, Eldad was recently diagnosed with lung cancer. After successfully fighting his illness with chemotherapy, his disease hit back and took his life. He left a wife to whom he had been married for almost 50 years, two daughters, and nine grandchildren. With his passing, the international movement disorders community lost one of their heroes—a man of great intellect, humanity, impeccable character, boundless energy, incomparable warmth, and an unforgettable sense of humor. Many of us have lost one of our dearest friends—someone whom we shall always remember.

Eldad Melamed was born in 1942 in Tel Aviv, after his parents had fled Europe to escape the Holocaust. He studied at the Hebrew University and the Hadassah Medical School in Jerusalem, and graduated with an MD degree in 1968. He then served 3 years as a military medical officer in a prestigious unit of the Israeli Defense Forces. Upon return to civilian life, Eldad completed a residency in Neurology at the Hadassah

Theoretical Scheme for the Development of PD

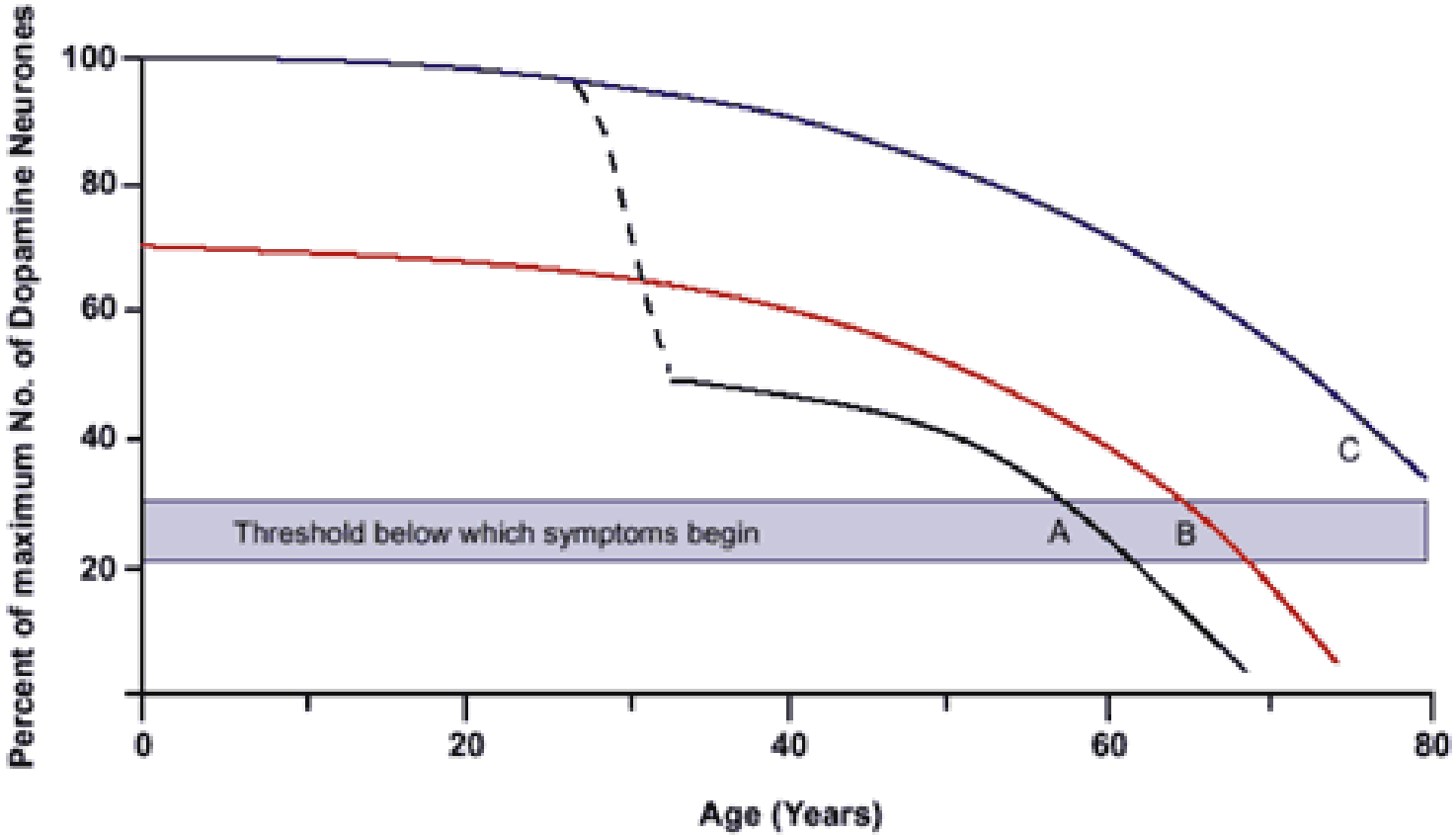

Science

Grafts of Fetal Dopamine Neurons Survive and Improve Motor Function in Parkinson's Disease

Olle Lindvall,* Patrik Brundin, Håkan Widner, Stig Rehncrona, Björn Gustavii, Richard Frackowiak, Klaus L. Leenders, Guy Sawle, John C. Rothwell, C. David Marsden, Anders Björklund

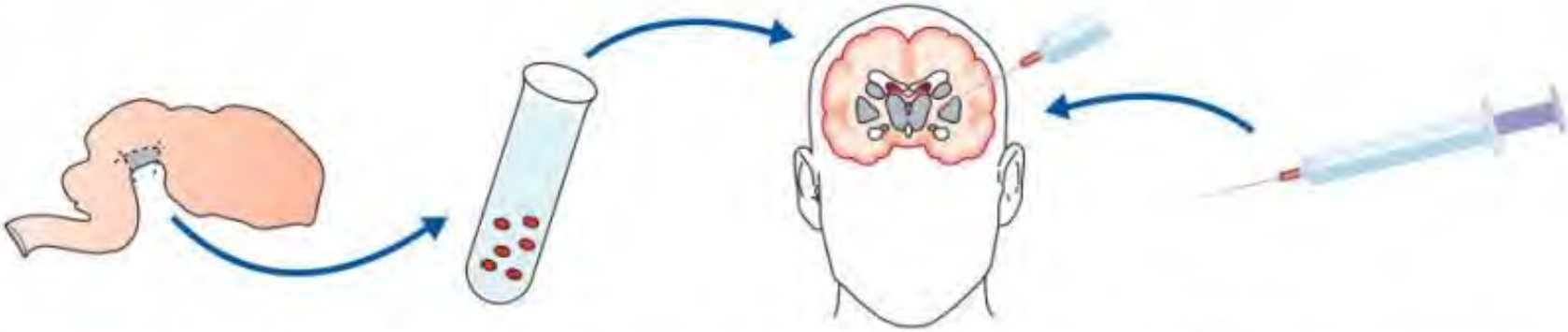

Dissection of ventral mesencephalic tissue
One to eight donor embryos used as a source of tissue

Transplant preparation
Fresh or hibernated tissue is homogenised into cell suspension or small tissue pieces

Grafting procedure
Stereotactic injection in caudate and/or putamen
Three to eight injection tracts per striatum

Immunosuppression
Ciclosporin for 6 months or long-term triple drug therapy (ciclosporin, azathioprine, prednisolone) to prevent rejection

The New England Journal of Medicine 2001;344(10):710-719

TRANSPLANTATION OF EMBRYONIC DOPAMINE NEURONS FOR SEVERE PARKINSON'S DISEASE

CURT R. FREED, M.D., PAUL E. GREENE, M.D., ROBERT E. BREEZE, M.D., WEI-YANN TSAI, PH.D., WILLIAM DUMOUCHEL, PH.D., RICHARD KAO, SANDRA DILLON, R.N., HOWARD WINFIELD, R.N., SHARON CULVER, N.P., JOHN Q. TROJANOWSKI, M.D., PH.D., DAVID EIDELBERG, M.D., AND STANLEY FAHN, M.D.

^{18}F-Fluorodopa Uptake

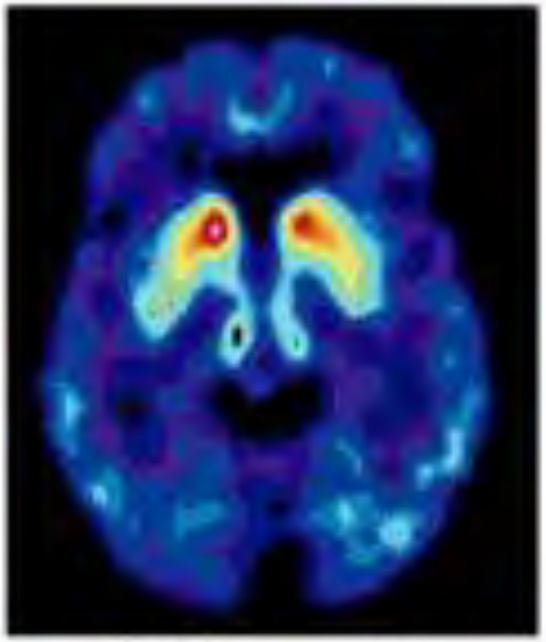

Before transplantation

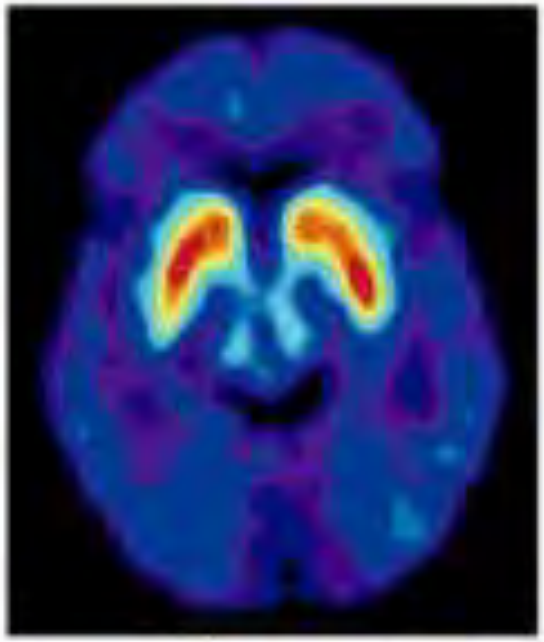

After transplantation

Annals of Neurology
Vol 45 No 4 April 1999

EXPEDITED PUBLICATION

A Double-blind Controlled Trial of Bilateral Fetal Nigral Transplantation in Parkinson's Disease

C. Warren Olanow, MD,[1] Christopher G. Goetz, MD,[2] Jeffrey H. Kordower, PhD,[2] A. Jon Stoessl, MD,[3] Vesna Sossi, PhD,[3] Mitchell F. Brin, MD,[1] Kathleen M. Shannon, MD,[2] G. Michael Nauert, MD,[4] Daniel P. Perl, MD,[5] James Godbold, PhD,[6] and Thomas B. Freeman, MD[4]

Annals of Neurology

EXPEDITED PUBLICATION

A Double-blind Controlled Trial of Bilateral Fetal Nigral Transplantation in Parkinson's Disease

C. Warren Olanow, MD,[1] Christopher G. Goetz, MD,[2] Jeffrey H. Kordower, PhD,[2] A. Jon Stoessl, MD,[3] Vesna Sossi, PhD,[3] Mitchell F. Brin, MD,[1] Kathleen M. Shannon, MD,[2] G. Michael Nauert, MD,[4] Daniel P. Perl, MD,[5] James Godbold, PhD,[6] and Thomas B. Freeman, MD[4]

Fetal nigral transplantation currently cannot be recommended as a therapy for PD based on these results

Many years later…

Dopamine Cell Implantation in Parkinson's Disease: Long-Term Clinical and ^{18}F-FDOPA PET Outcomes

Yilong Ma[1,2], Chengke Tang[1], Thomas Chaly[1,2], Paul Greene[3], Robert Breeze[4], Stanley Fahn[3], Curt Freed[5], Vijay Dhawan[1,2], and David Eidelberg[1,2]

[1]Center for Neurosciences, The Feinstein Institute for Medical Research, Manhasset, New York; [2]Departments of Neurology and Medicine, North Shore University Hospital and New York University School of Medicine, Manhasset, New York; [3]Department of Neurology, Columbia College of Physicians and Surgeons, New York, New York; [4]Department of Neurosurgery, University of Colorado School of Medicine, Denver, Colorado; and [5]Neuroscience Center and Division of Clinical Pharmacology and Toxicology, University of Colorado School of Medicine, Denver, Colorado

<u>Conclusion</u>: These results suggest that clinical benefit and graft viability are sustained up to 4 y after transplantation. Moreover, the dependence of clinical (but not imaging) outcomes on subject age and sex at 1 y may not persist over the long term. Last, the imaging changes reliably correlate with clinical outcome over the entire posttransplantation time course.

Many years later…

nature medicine

Dopamine neurons implanted into people with Parkinson's disease survive without pathology for 14 years

Ivar Mendez[1,6], Angel Viñuela[2,6], Arnar Astradsson[2], Karim Mukhida[1], Penelope Hallett[2], Harold Robertson[1], Travis Tierney[2,3], Renn Holness[1], Alain Dagher[4], John Q Trojanowski[5] & Ole Isacson[2]

Many years later…

BRIEF COMMUNICATIONS

nature medicine

Lewy bodies in grafted neurons in subjects with Parkinson's disease suggest host-to-graft disease propagation

Jia-Yi Li[1], Elisabet Englund[2], Janice L Holton[3], Denis Soulet[1], Peter Hagell[4], Andrew J Lees[3], Tammaryn Lashley[3], Niall P Quinn[5], Stig Rehncrona[6], Anders Björklund[7], Håkan Widner[4], Tamas Revesz[3,9], Olle Lindvall[4,8,9] & Patrik Brundin[1,9]

Two subjects with Parkinson's disease who had long-term survival of transplanted fetal mesencephalic dopaminergic neurons (11–16 years) developed α-synuclein–positive Lewy bodies in grafted neurons. Our observation has key implications for understanding Parkinson's pathogenesis by providing the first evidence, to our knowledge, that the disease can propagate from host to graft cells. However, available data suggest that the majority of grafted cells are functionally unimpaired after a decade, and recipients can still experience long-term symptomatic relief.

bilateral implantation of fetal mesencephalic tissue into the putamen (subject 3 in the Lund series; left graft 16 years before death, right graft 12 years before death) or both putamen and caudate nucleus (subject 8; left graft 13 years before death, right graft 11 years before death)[6]. Graft survival was confirmed by clinical improvement at 5 months up to at least 3 years after surgery in subject 3 (ref. 6).

Both subjects died from causes unrelated to grafting (**Supplementary Methods** online). In their substantiae nigrae, the subjects had histopathological changes characteristic of Parkinson's disease: severe

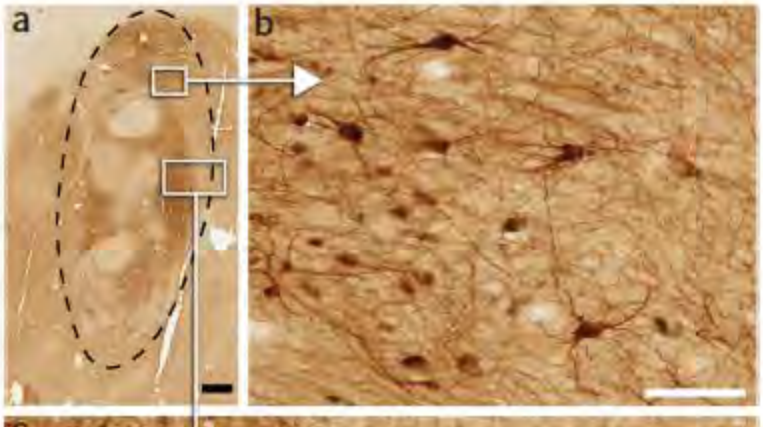

Fetal transplantation - Conclusions

- Human fetal mesencephalic dopaminergic neurons survive transplantation into the brain of Parkinson's patients (11 papers)
- The grafts can survive despite an ongoing disease process, unaltered by continuous anti-parkinsonian drug treatment
- Histopathological analyses have confirmed survival of the dopaminergic grafts and demonstrated their ability to reinnervate the striatum.
- These grafts can restore regulated release of dopamine in the striatum
- The transplanted fetal cells can become functionally integrated into existing neural networks of the PD patient

Fetal mesencephalic cells- problems

- very low yield of dopaminergic cells
- very low tissue availability
- no proven efficacy in controlled trials

  Freed et al, NEJM 2001; Olanow et al, Ann Neurol 2003

- “off- medication” dyskinesia- a serious side- effect

Stem Cell Replacement Therapy in PD

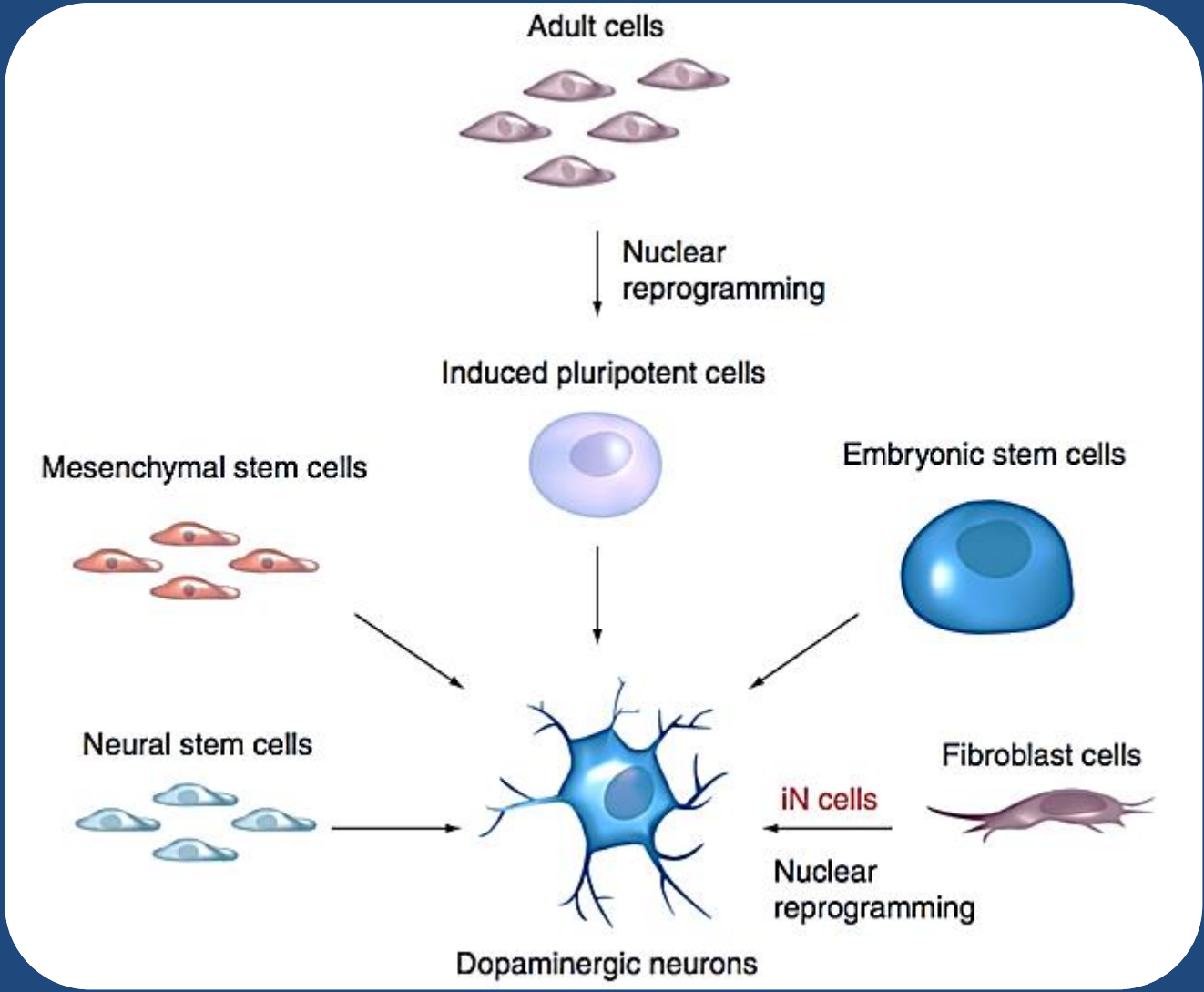

Ganz et al.

Stem Cell Replacement Therapy in PD

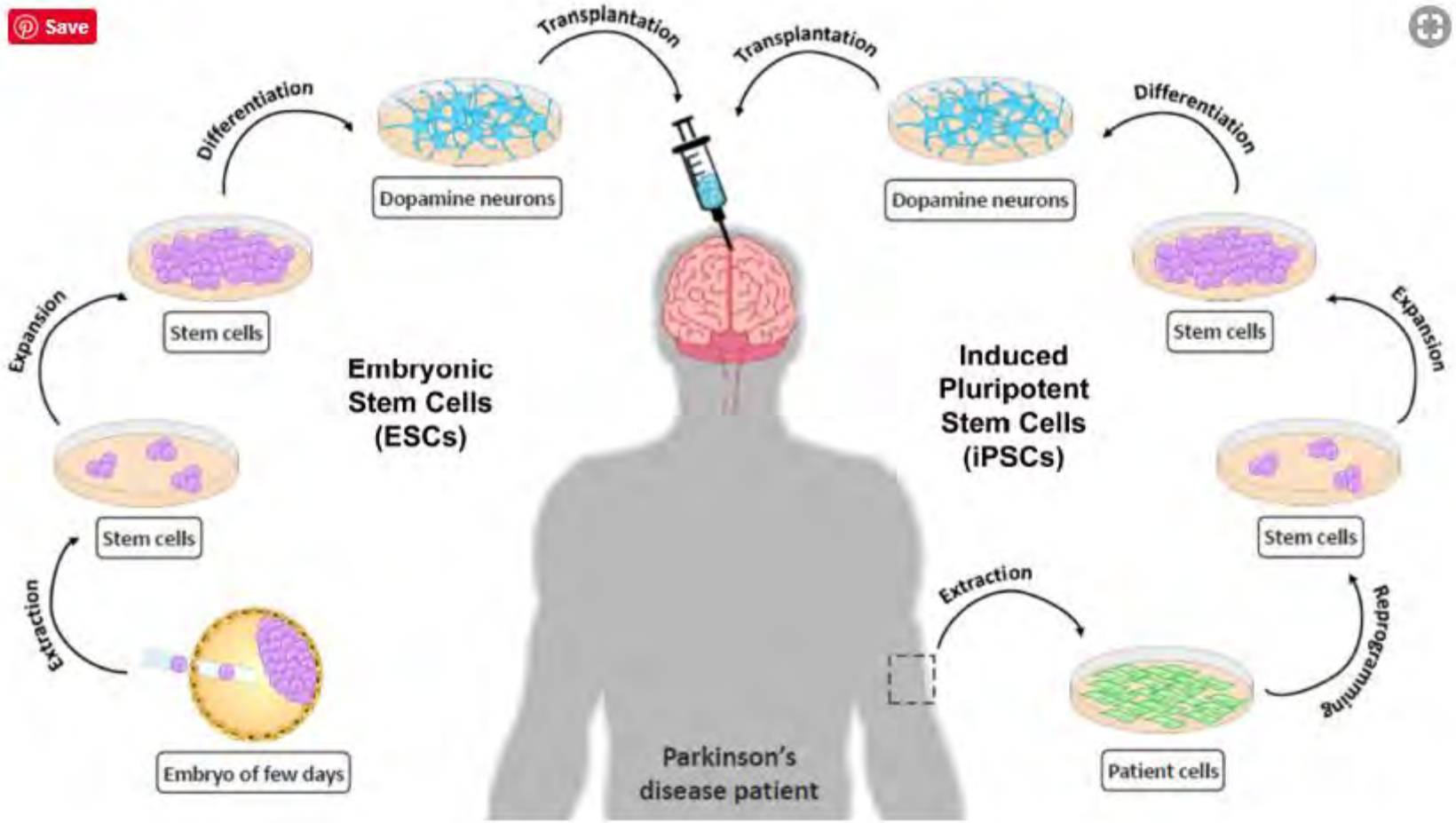

Cells used for in PD

Utilization of ESC, IPS, iN and fetal NSC is accompanied by a lot of **ethical and unpractical considerations**

Adult stem cells are **safe and easy access stem cells sources** for the development of cell therapies in PD

Sources of Mesenchymal Stem Cell

Bone Marrow



Adipose Tissue

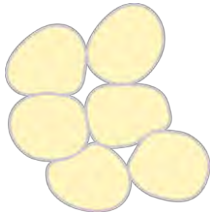

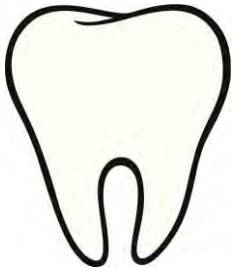

Dental Pulp

Amniotic Fluid

Placenta

Cord Blood

Stem cells differentiation

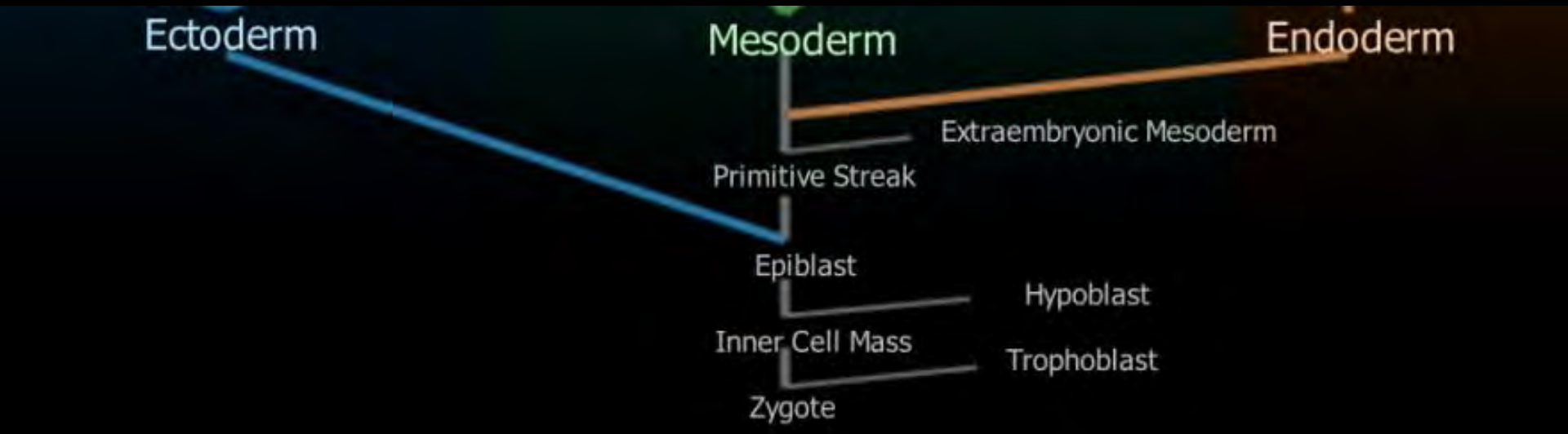

LifeMap Discovery™

New source for neural cells

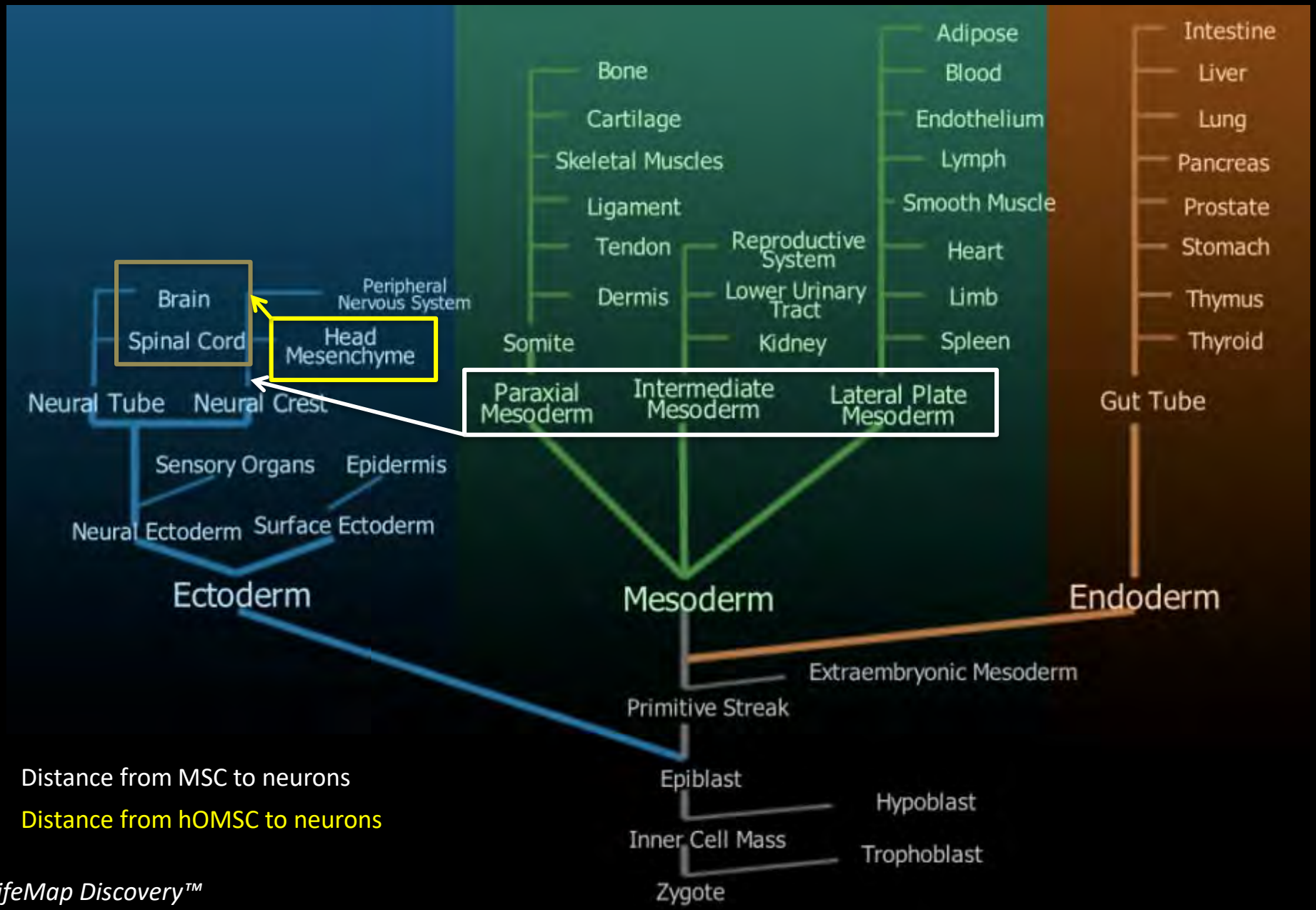

Distance from MSC to neurons

Distance from hOMSC to neurons

LifeMap Discovery™

Oral Mucosa, heals by regeneration without scar formation – age independent

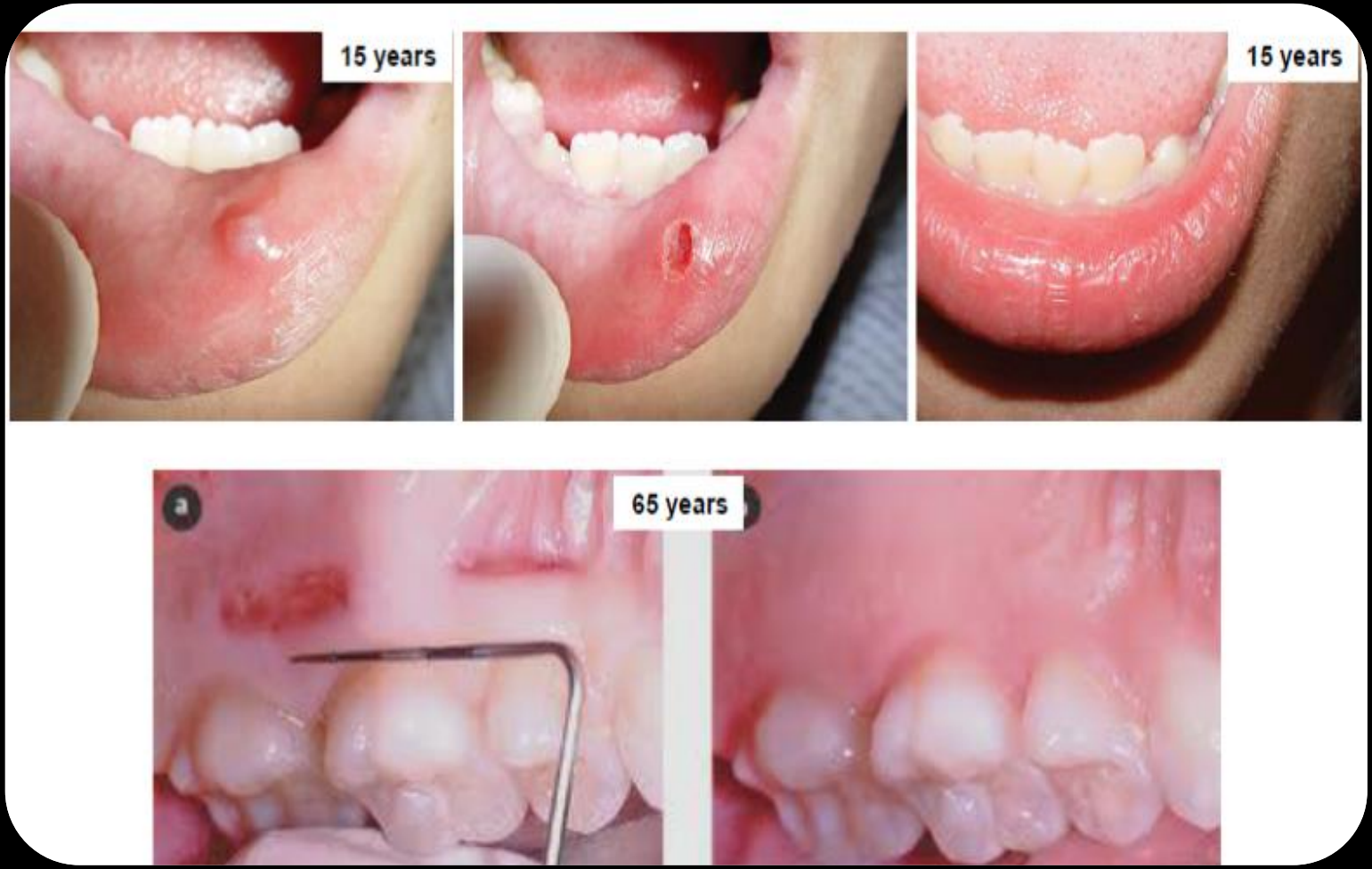

Human Oral Mucosa Stem Cells (hOMSC)

STEM CELLS
TISSUE-SPECIFIC STEM CELLS

The Lamina Propria of Adult Human Oral Mucosa Harbors a Novel Stem Cell Population

KEREN MARYNKA-KALMANI,[a] SANDRA TREVES,[a] MIRI YAFEE,[a] HELED RACHIMA,[b] YOSSI GAFNI,[a] MALKIEL A. COHEN,[c] SANDU PITARU[a]

[a]Department of Oral Biology, School of Dental Medicine Faculty of Medicine, Tel Aviv University, Tel Aviv;

① hOMSC niche is accessible

② easily obtained by non-invasive procedures

③ potential doesn't decrease with age

④ abundant cell availability (trillions in small biopsies)

The neural crest is the origin of the oral mucosa

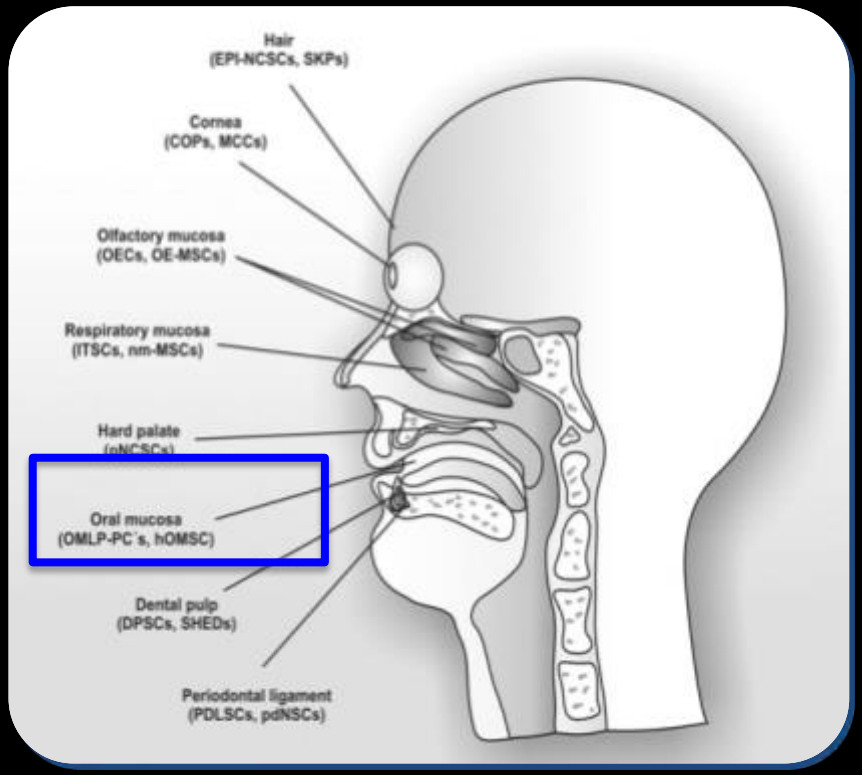

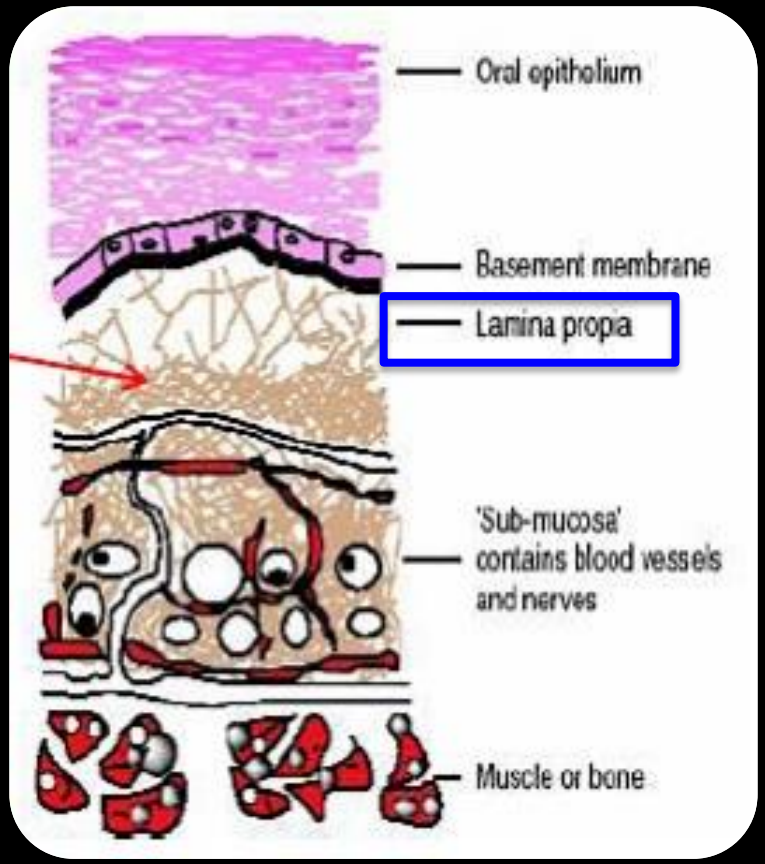

Kaltschmidt et al. 2011

Pluripotent marker expression

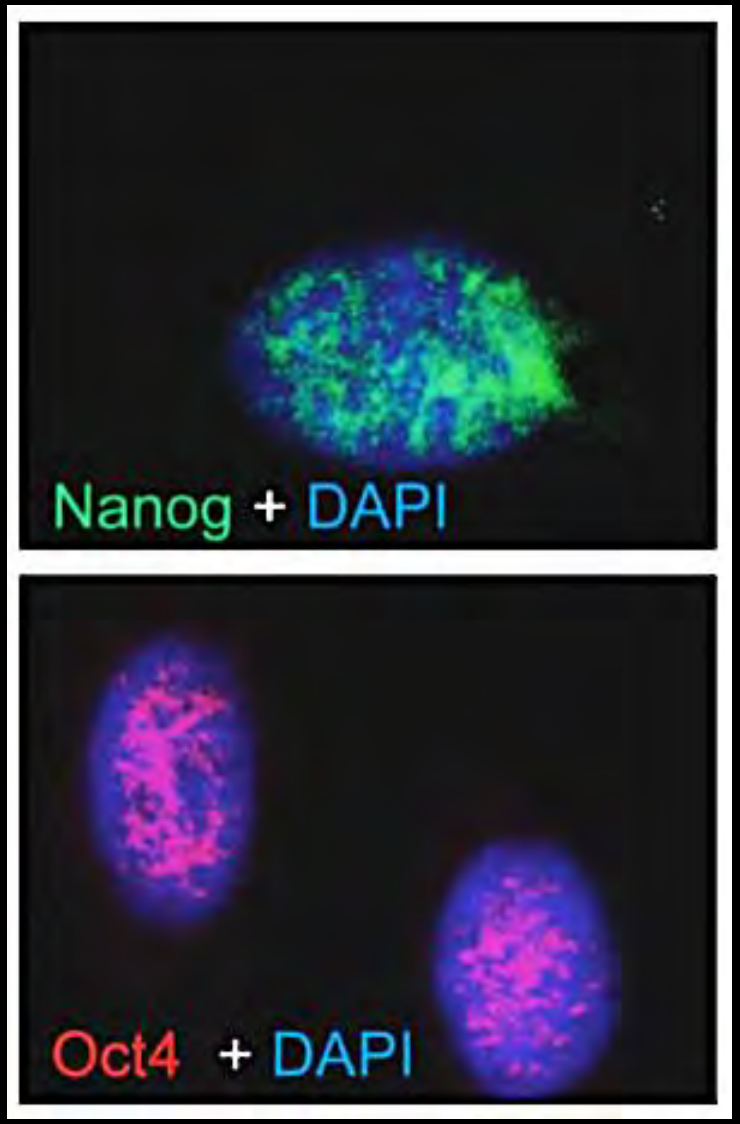

Negligibly affected by donors' age

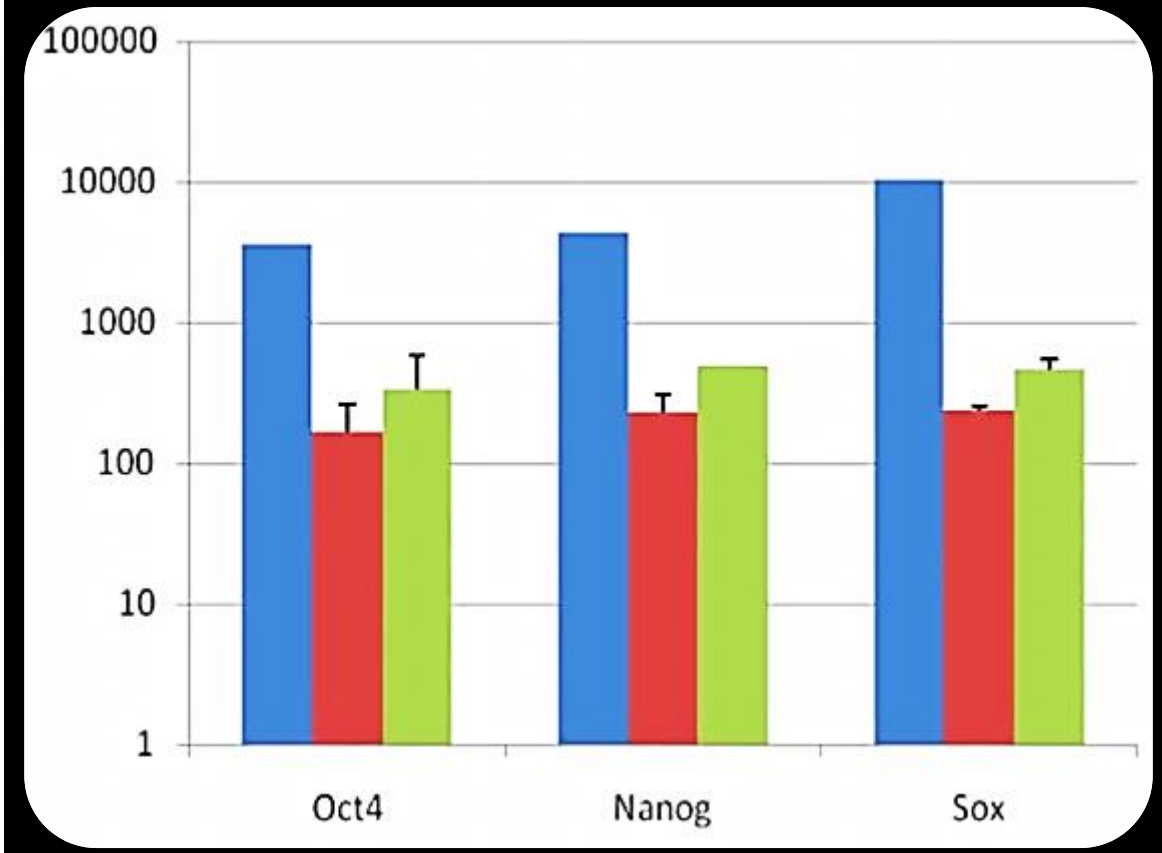

ESC Young Elder

Marynka-Kalmani et al.

The oral mucosa express pluripotency and neural crest markers

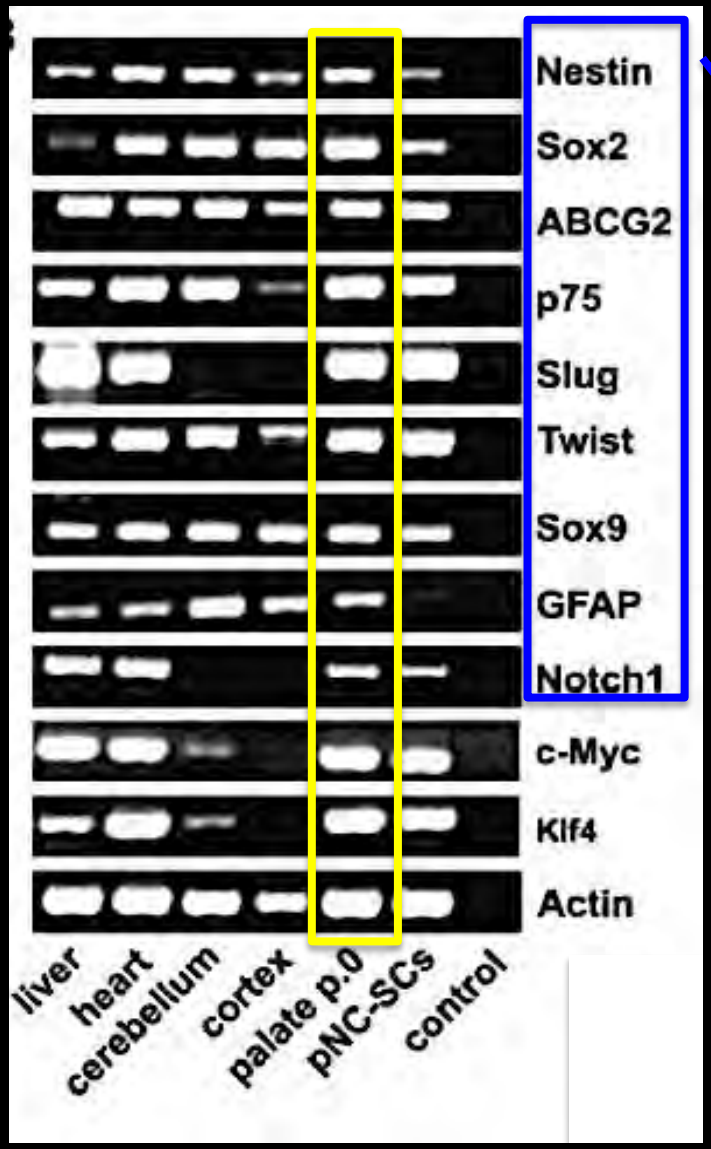

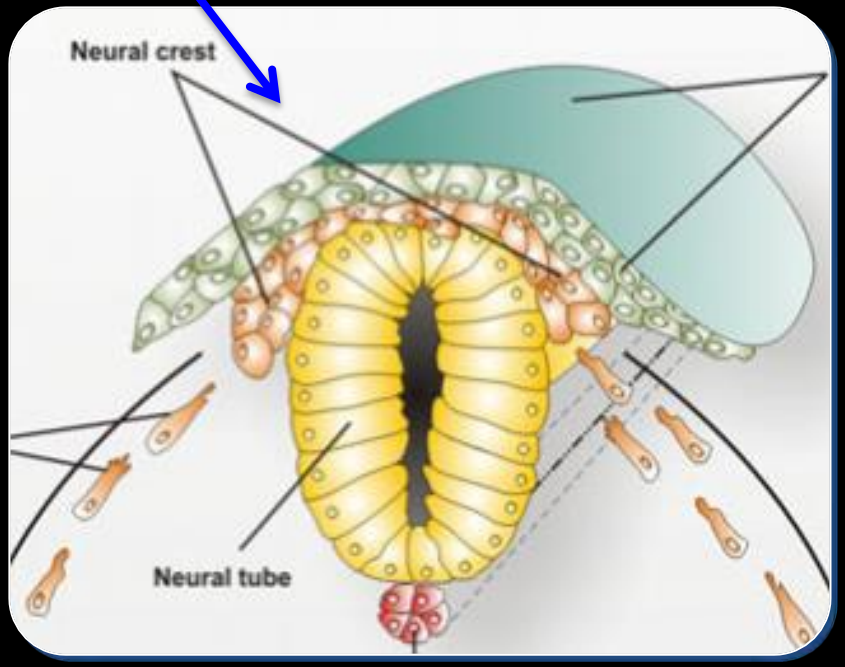

Our aim

Differentiate hOMSC to dopaminergic-like neurons for cell replacement in mice model of PD

Basal state hOMSC, revealed a specific set of neuronal and dopaminergic markers

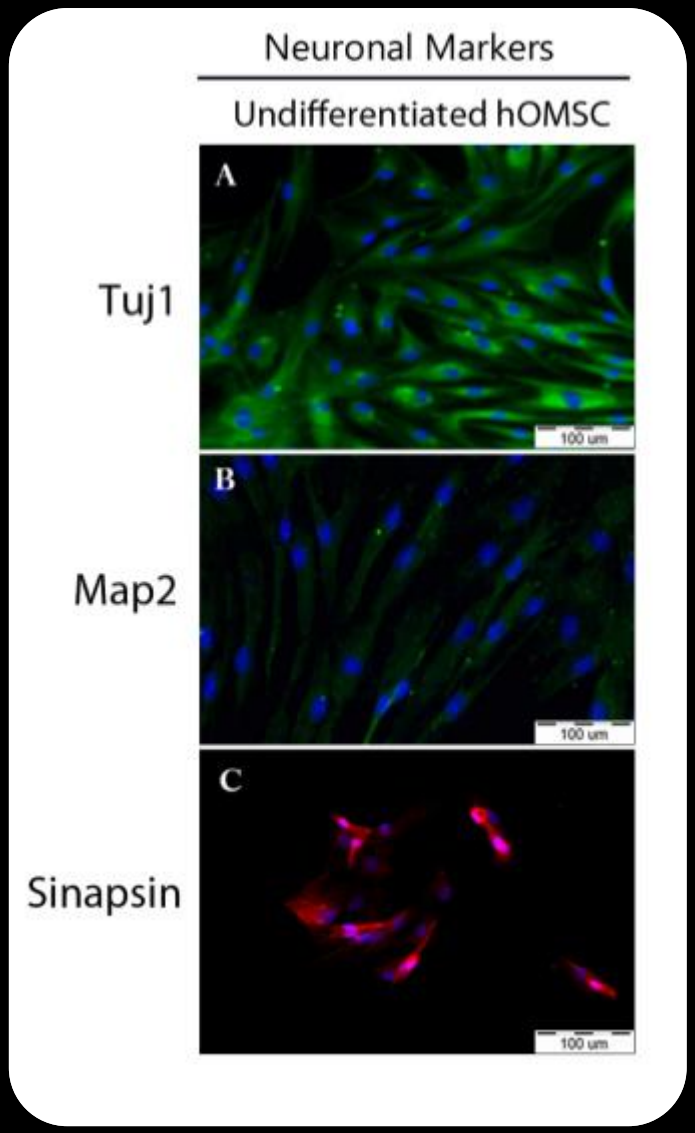

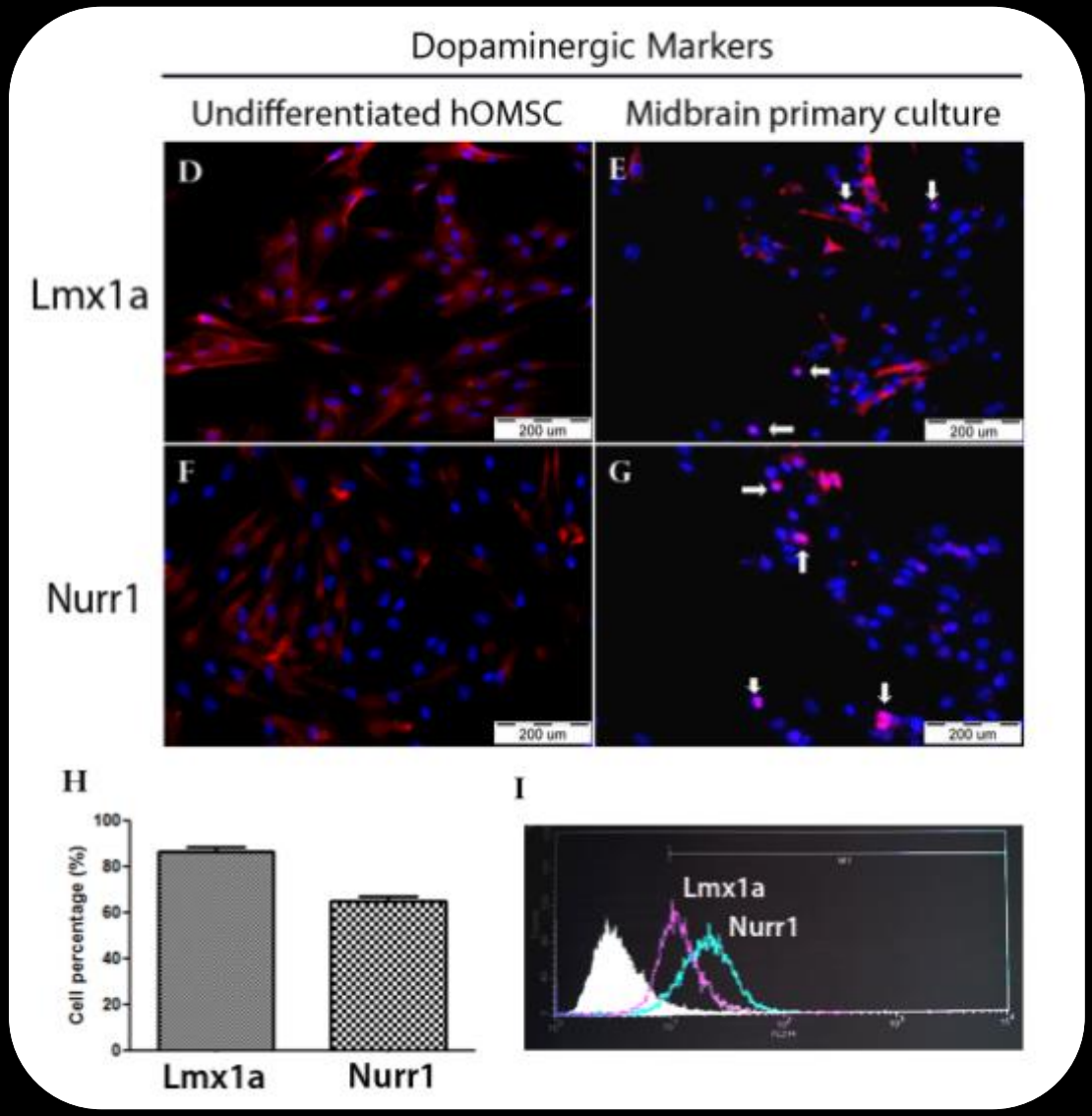

Dopaminergic differentiation protocol

hOMSC

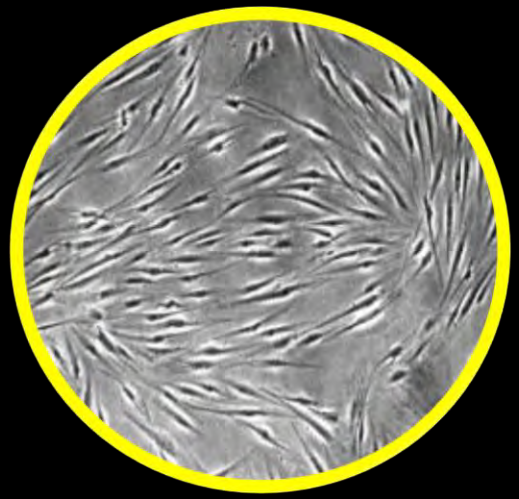

15 days

SHH
FGF-2
FGF-8
Wnt1
BDNF
N2

hOMSC-DA

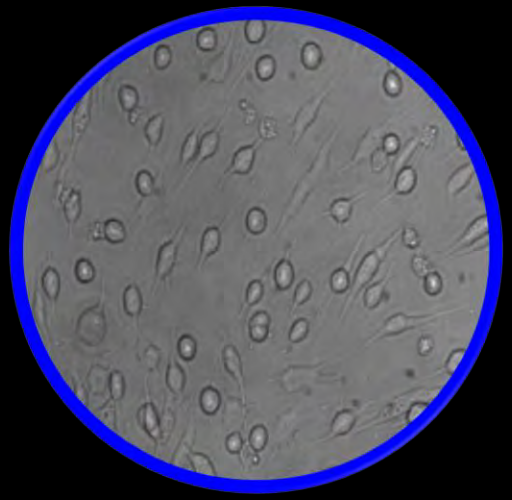

hOMSC after differentiation show neural-like morphology

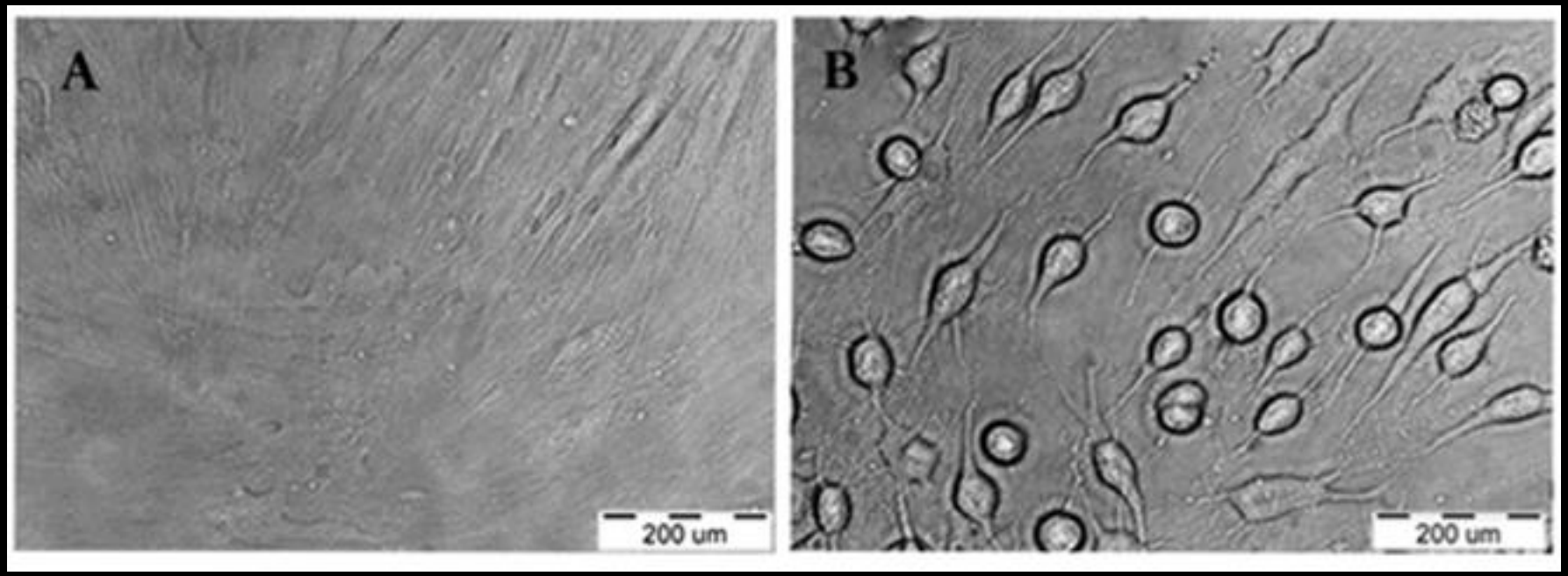

hOMSC after differentiation show neural-like morphology

Naive

Neuronal induction

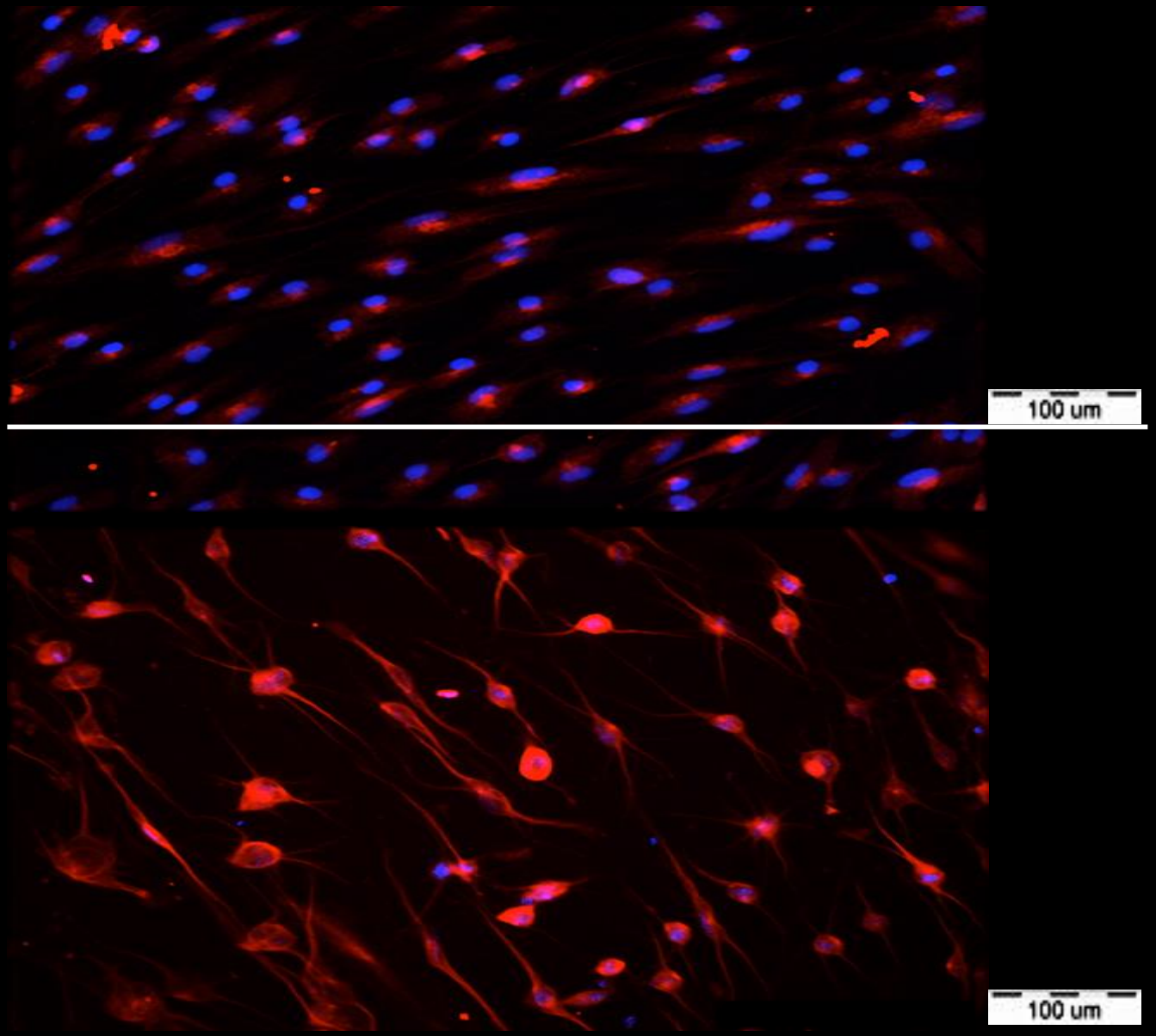

TUJ1/DAPI

DA phenotype was induced after differentiation

Pluripotent markers

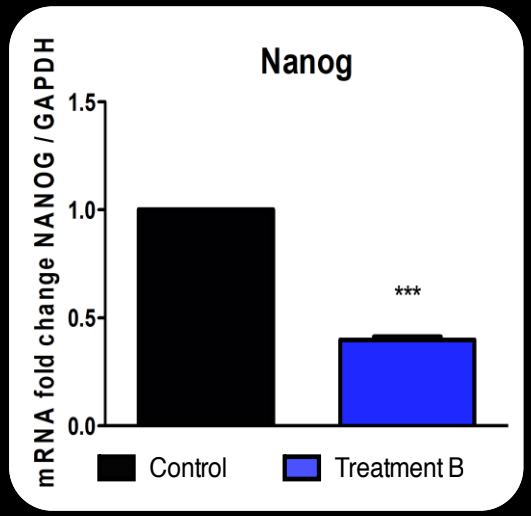

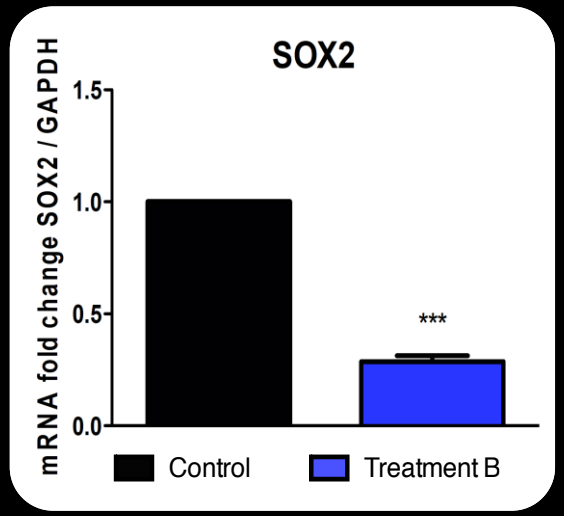

Neuronal marker

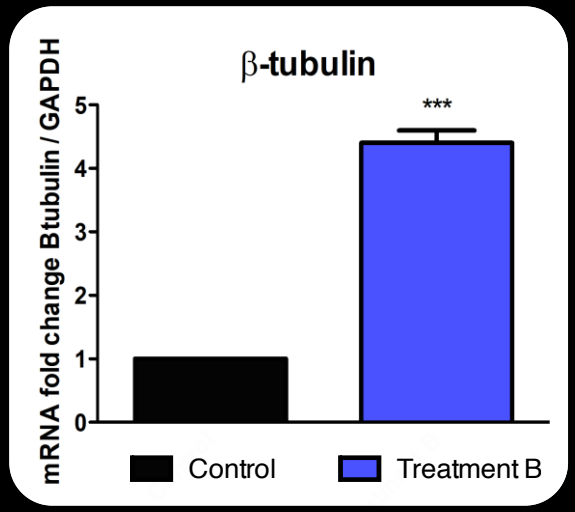

Dopaminergic markers

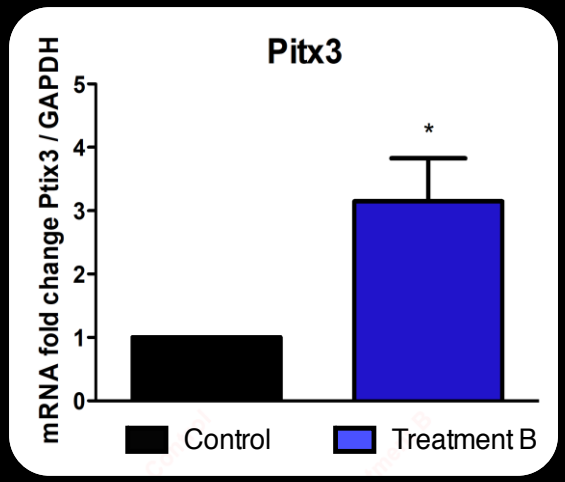

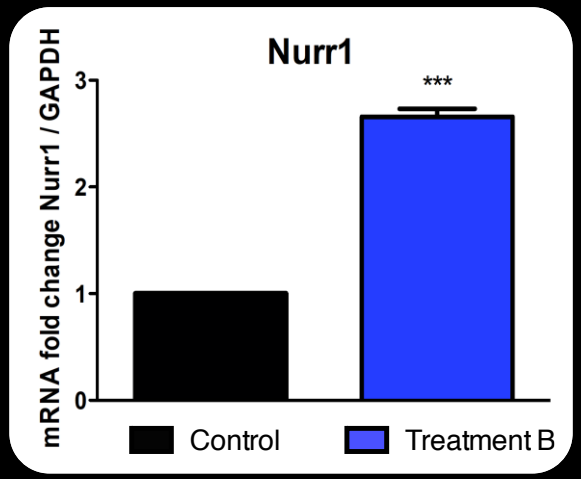

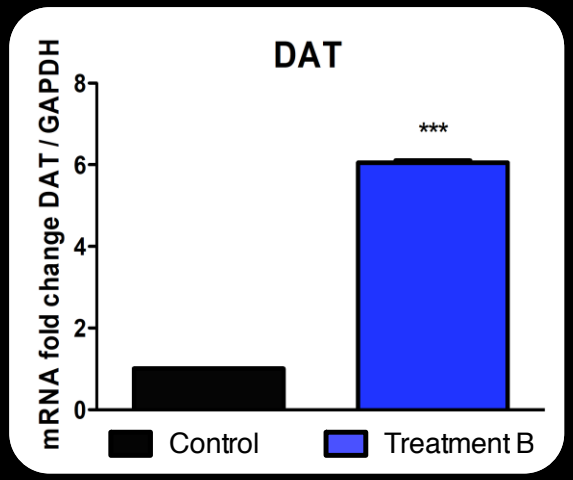

hOMSC after differentiation show neural-like morphology

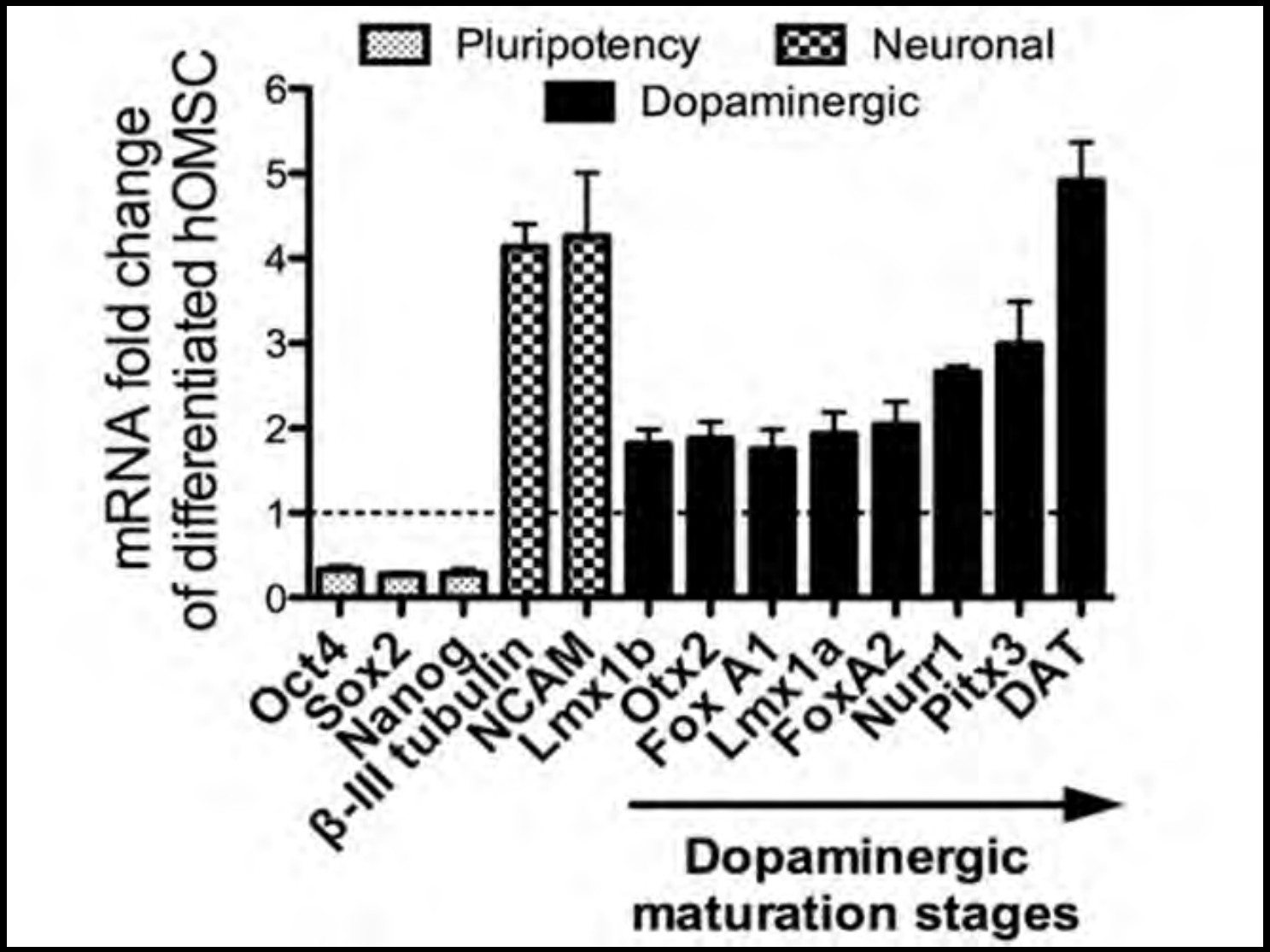

Dopaminergic transcription factors increase and nuclear translocation

Naive

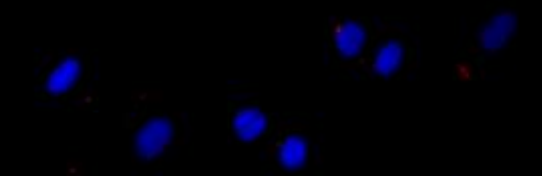

Differentiated

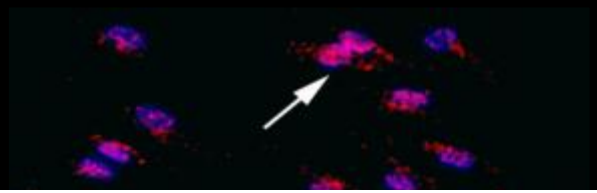

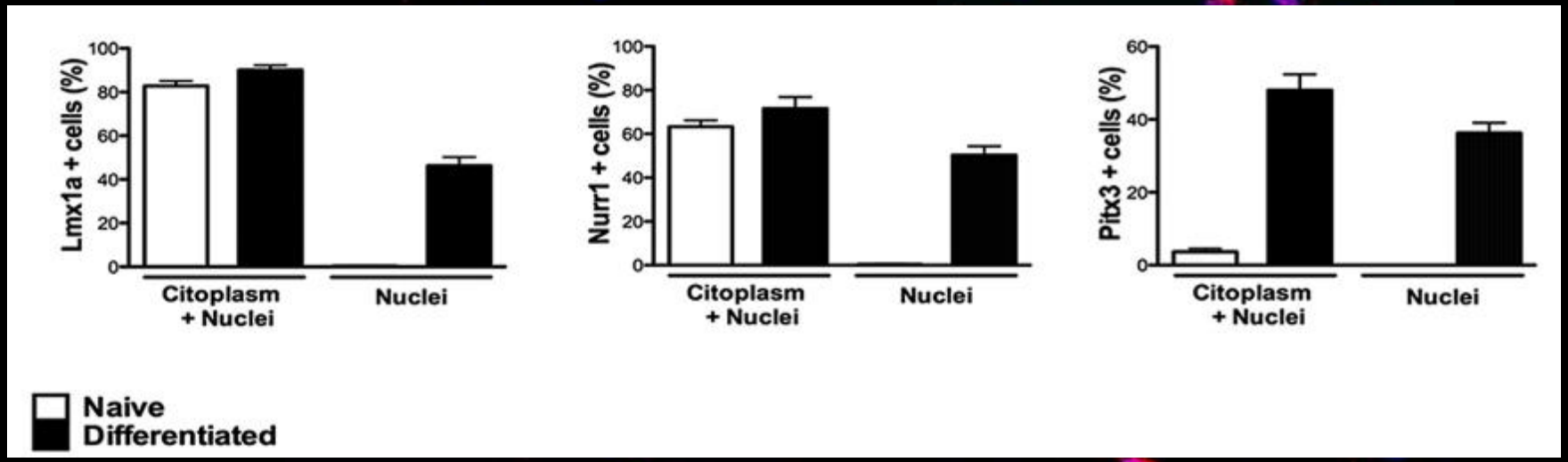

Nurr1

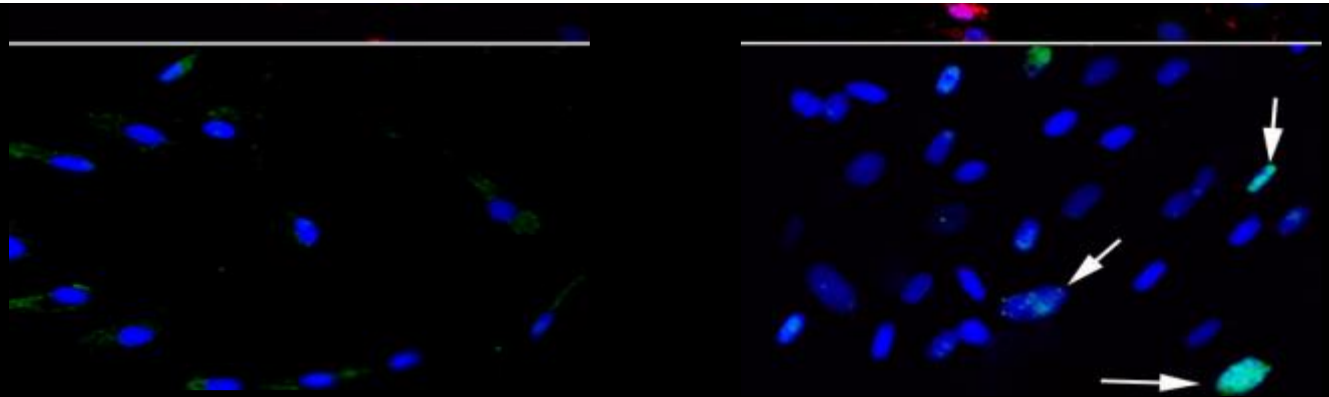

Dopaminergic transcription factors increase and nuclear translocation

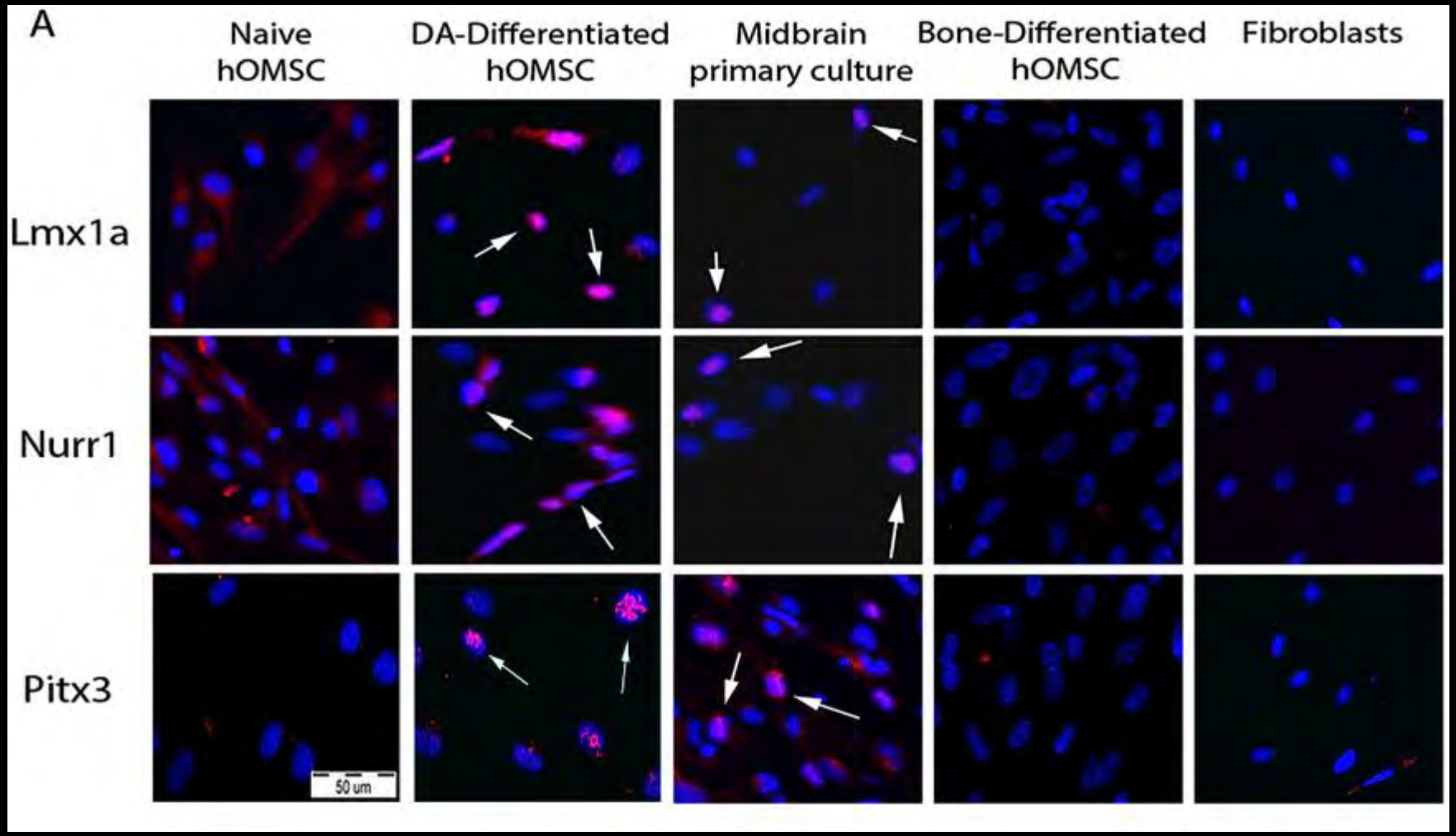

Mature dopaminergic markers (TH and PITX3) increase after differentiation

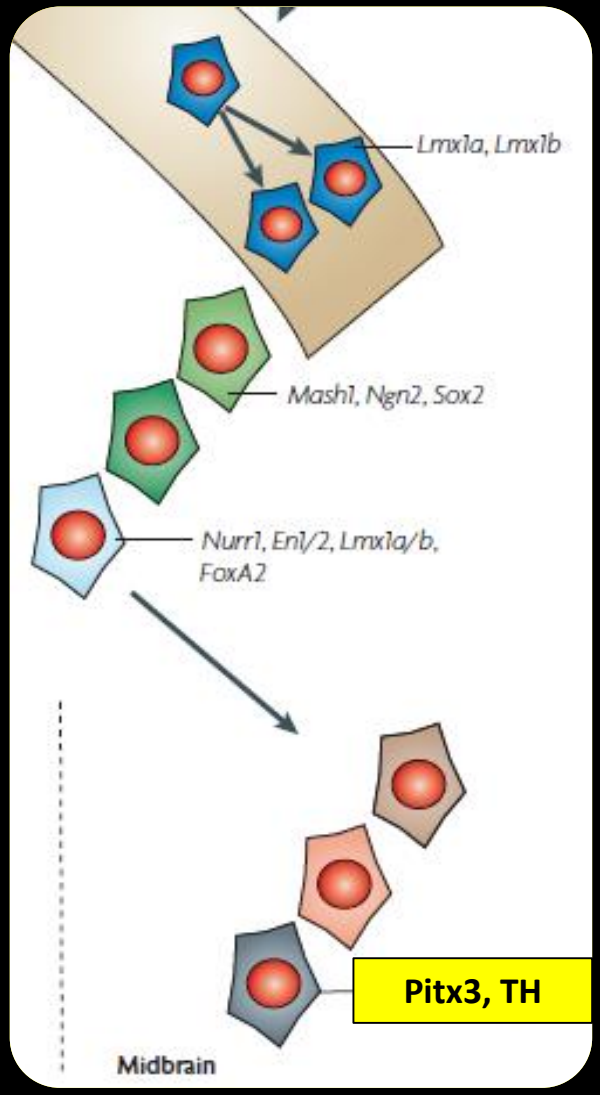

Mature dopaminergic markers (TH and PITX3) increase after differentiation

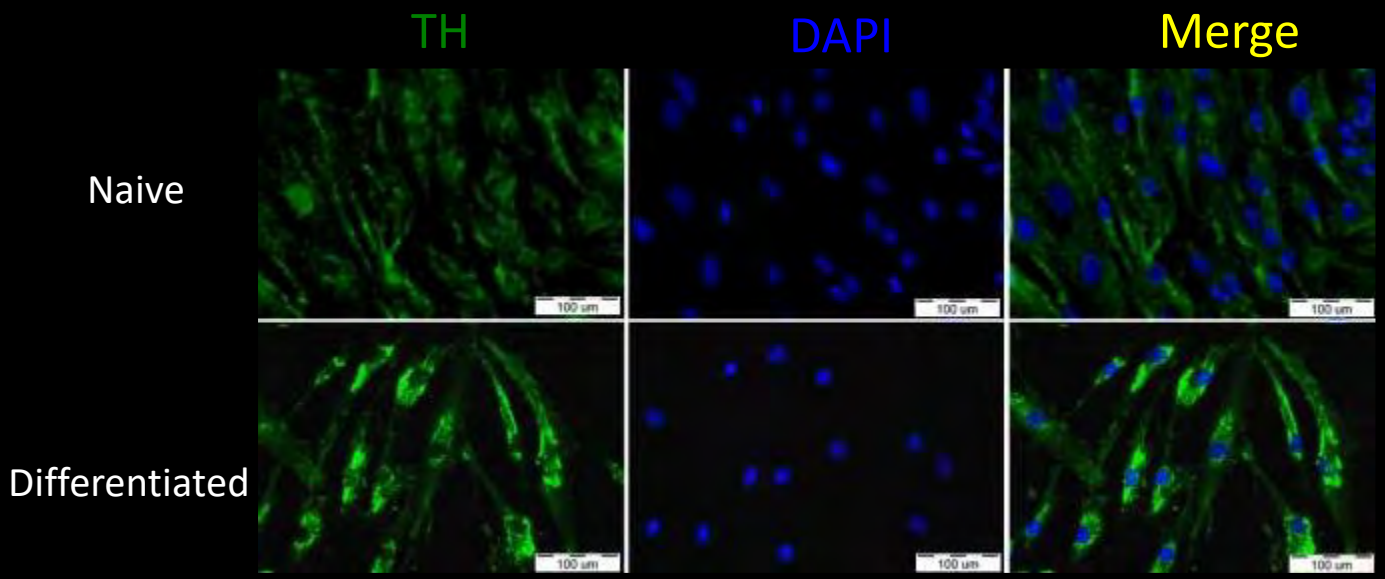

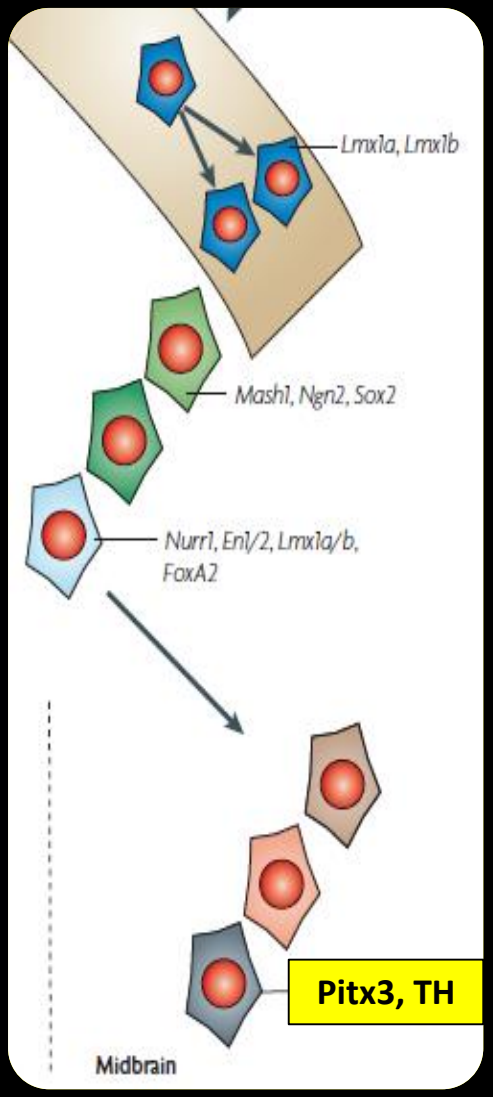

Mature dopaminergic markers (TH and PITX3) increase after differentiation

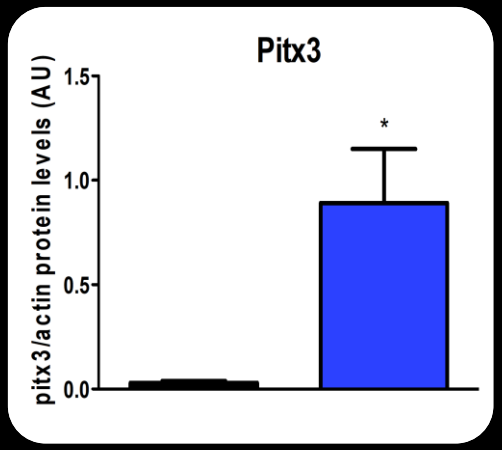

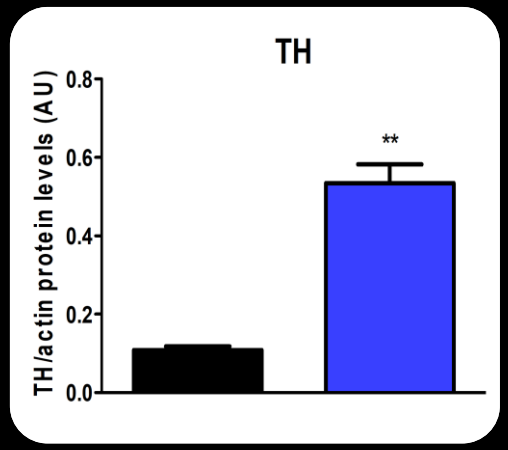

Western blot

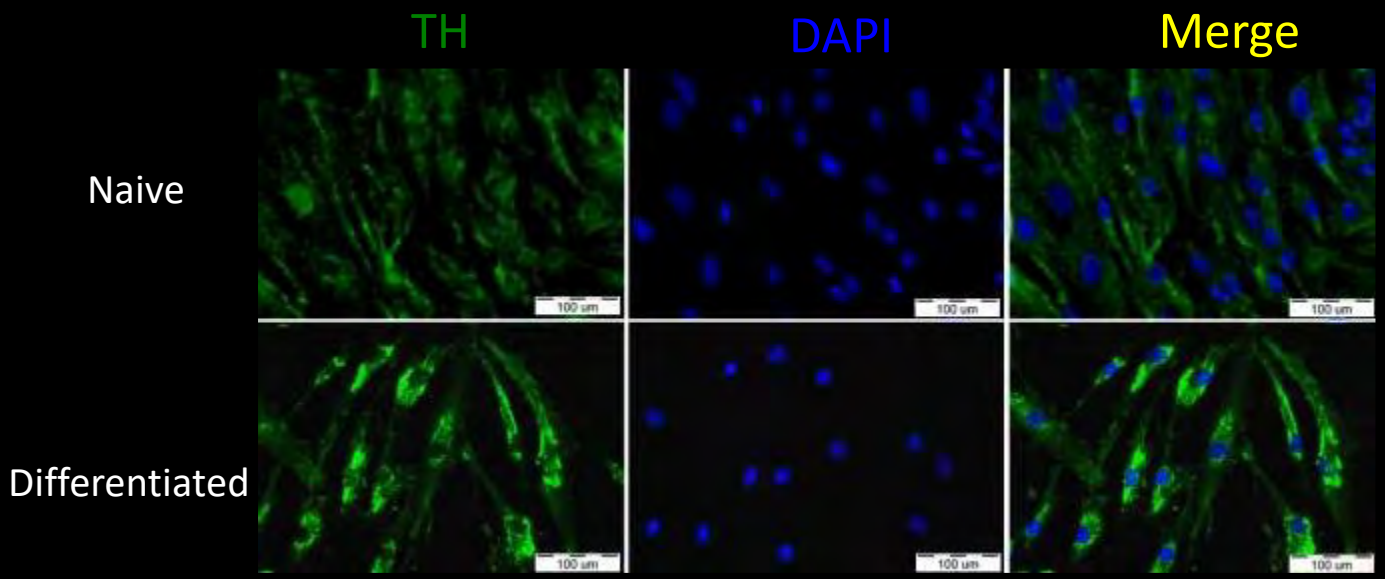

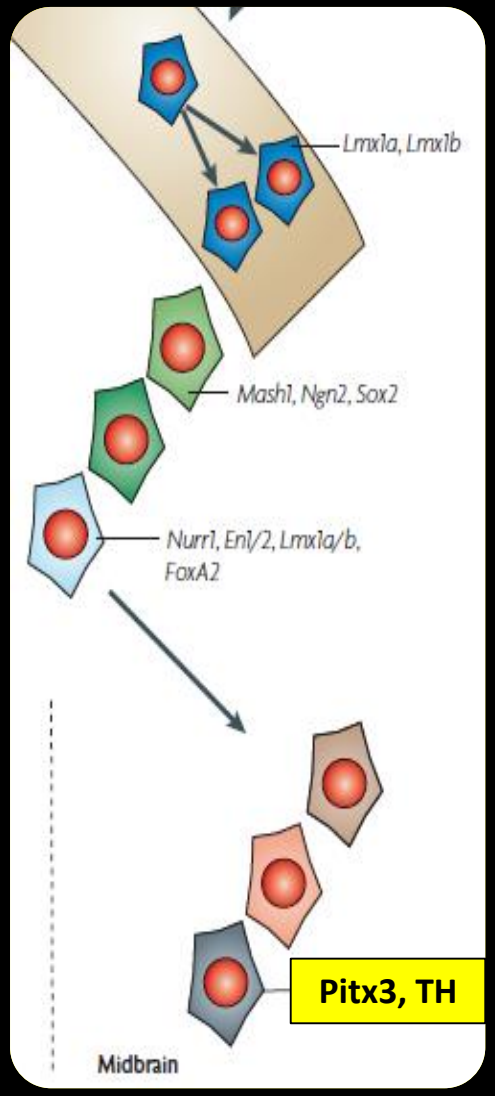

Induced hOMSC show a mature dopaminergic-like phenotype in vitro

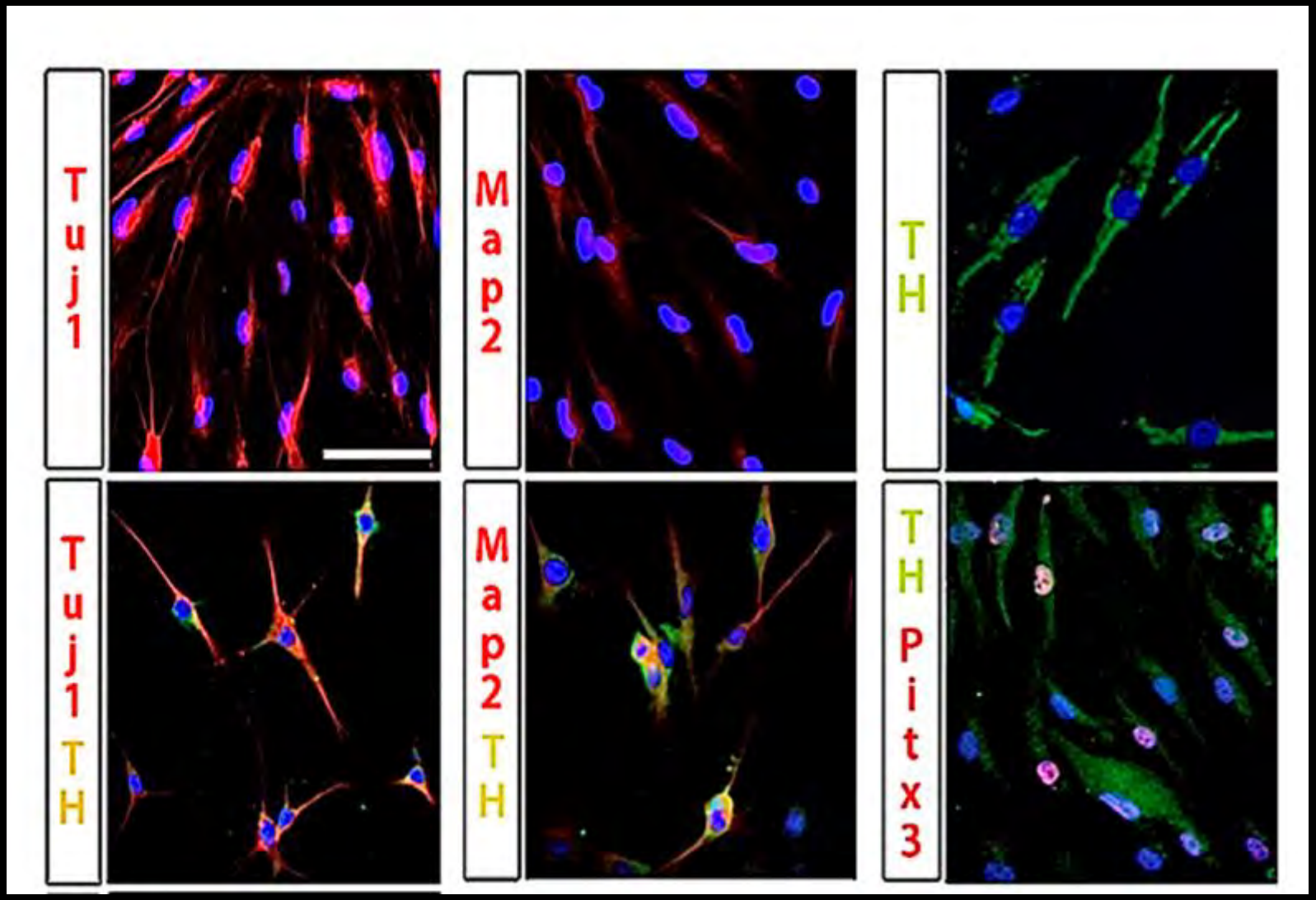

Regulated dopamine release after differentiation

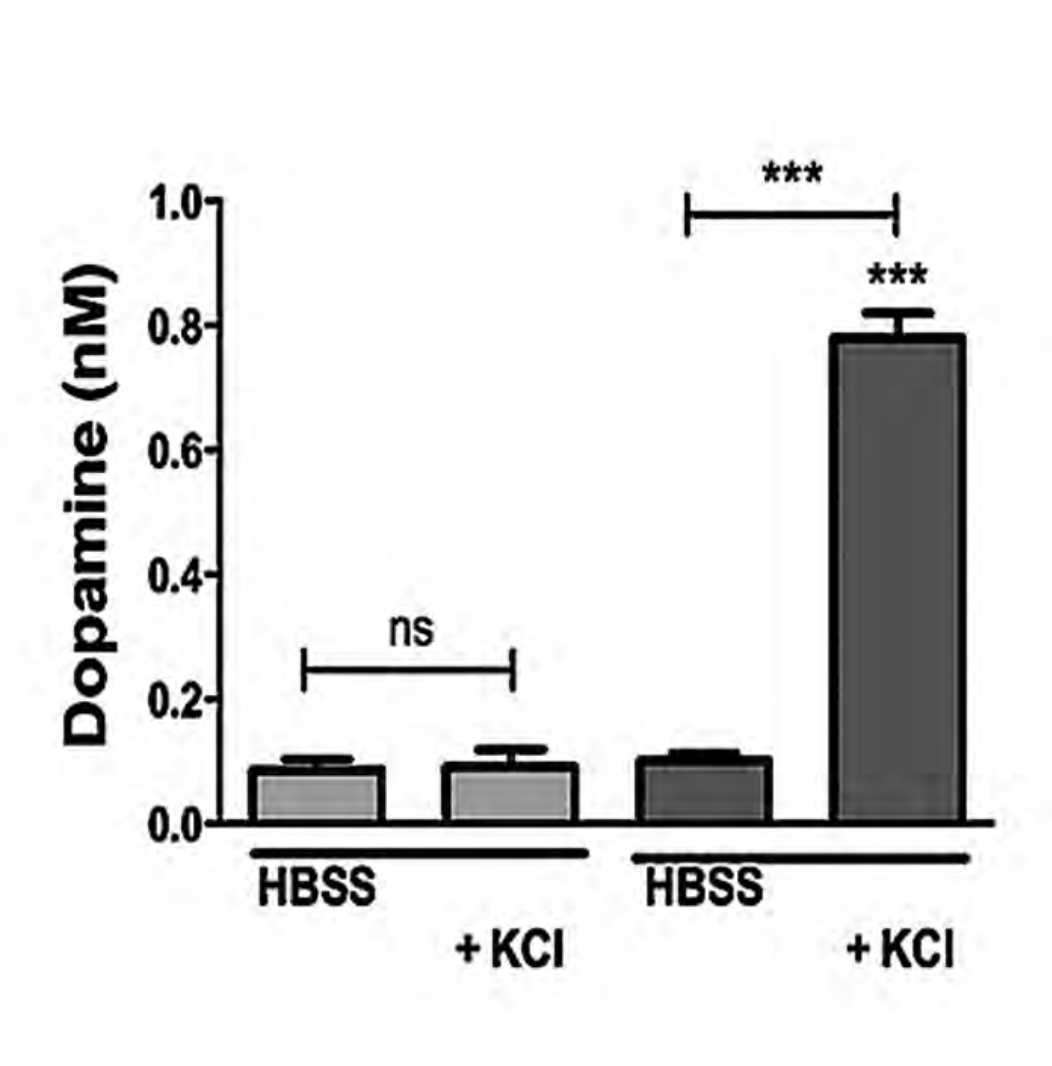

- Dopamine release measured by HPLC
  Cells incubated in HBSS (6mL) with or without KCl for 35 min

6-OHDA Parkinson's Disease Rat Model

Healthy Striatum

injured Striatum

Graft site
(2 x 400.000 cells)
PKH red labelling

Striatum
TH staining

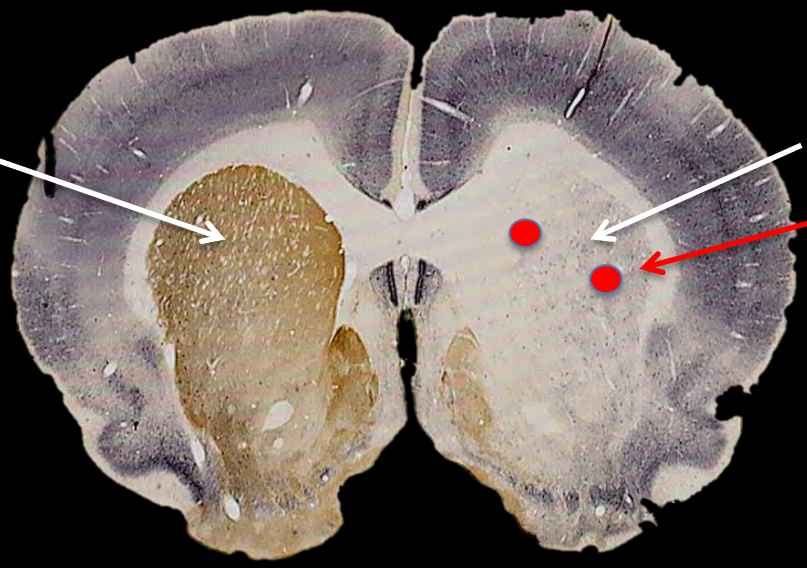

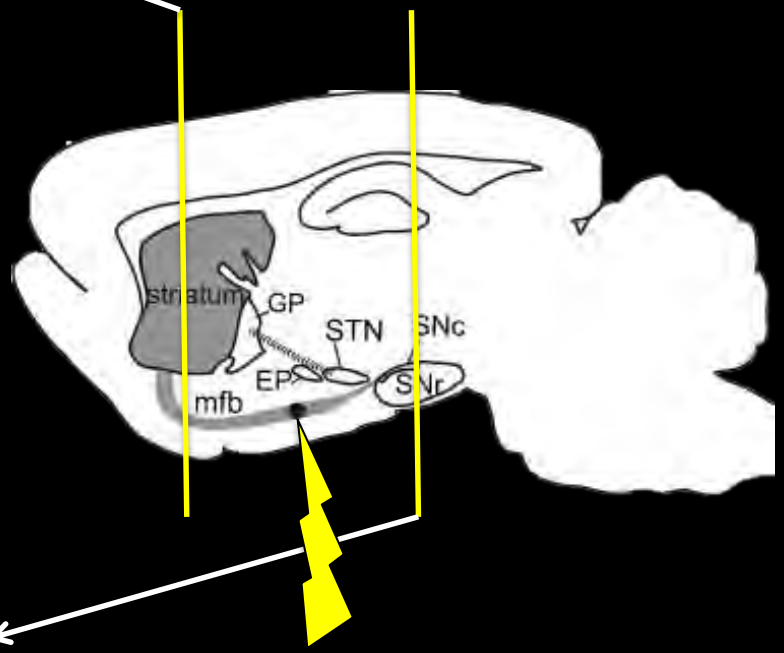

Substantia Nigra
TH staining

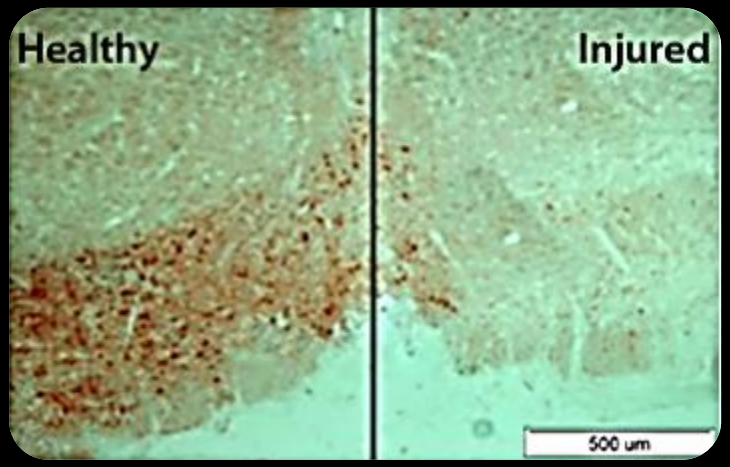

6-OHDA
Medial Forebrain Bundle

Transplanted DA-hOMSC improve behavioral parameters in a rat model of PD:

Amphetamine induced-rotations



Transplanted DA-hOMSC improve behavioral parameters in a rat model of PD: Cylinder Test

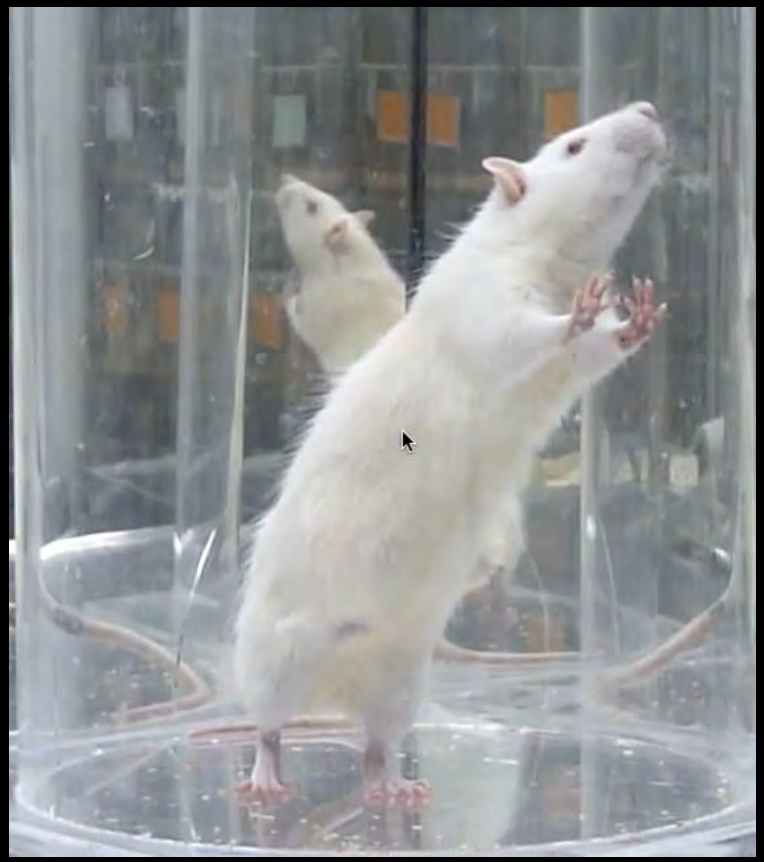

3 weeks post-transplantation

Transplanted DA-hOMSC improve behavioral parameters in a rat model of PD: Rotor-Rod



TH detection in the affected striatum 10 weeks post-transplantation

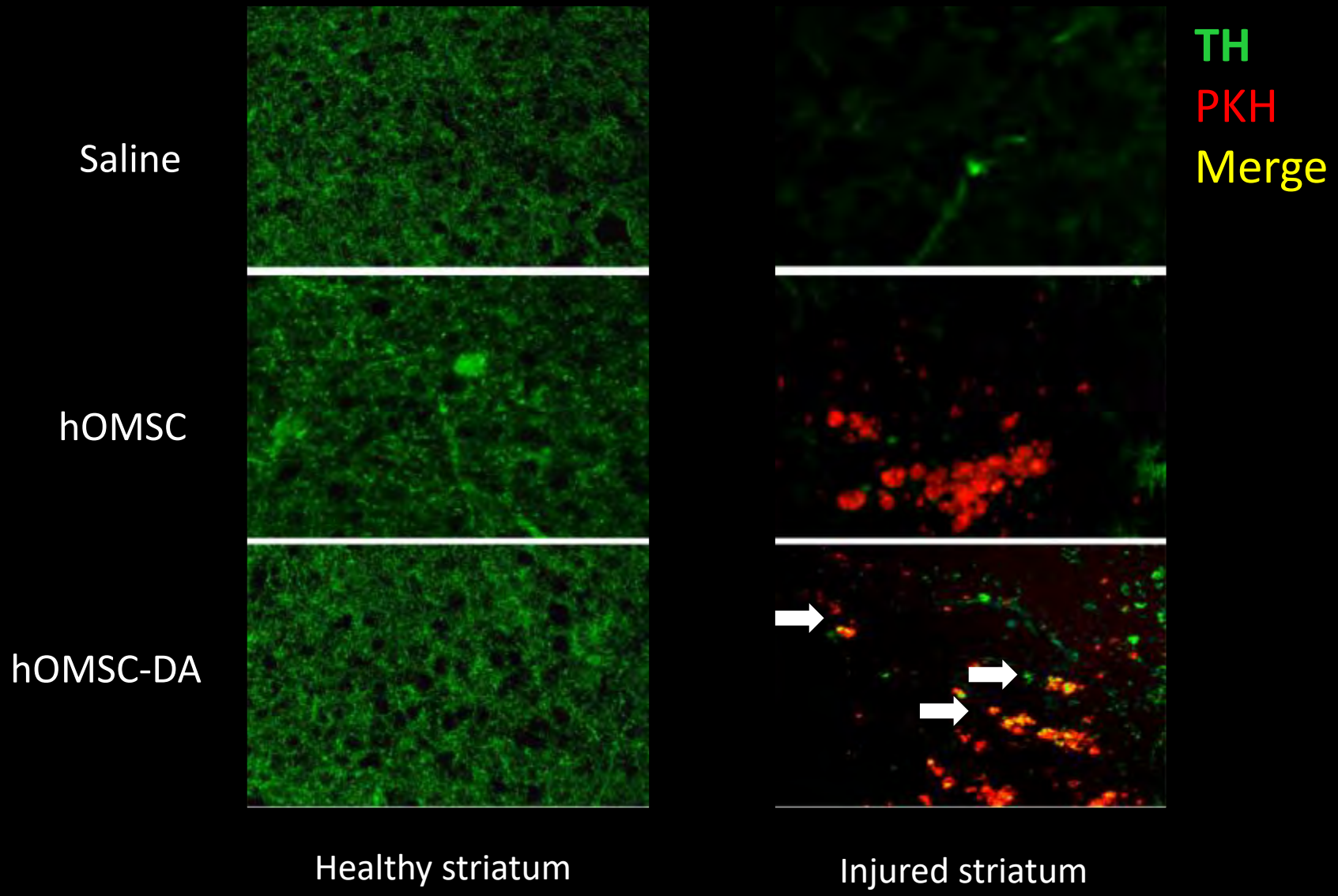

Increased DA levels 10 weeks after transplantation

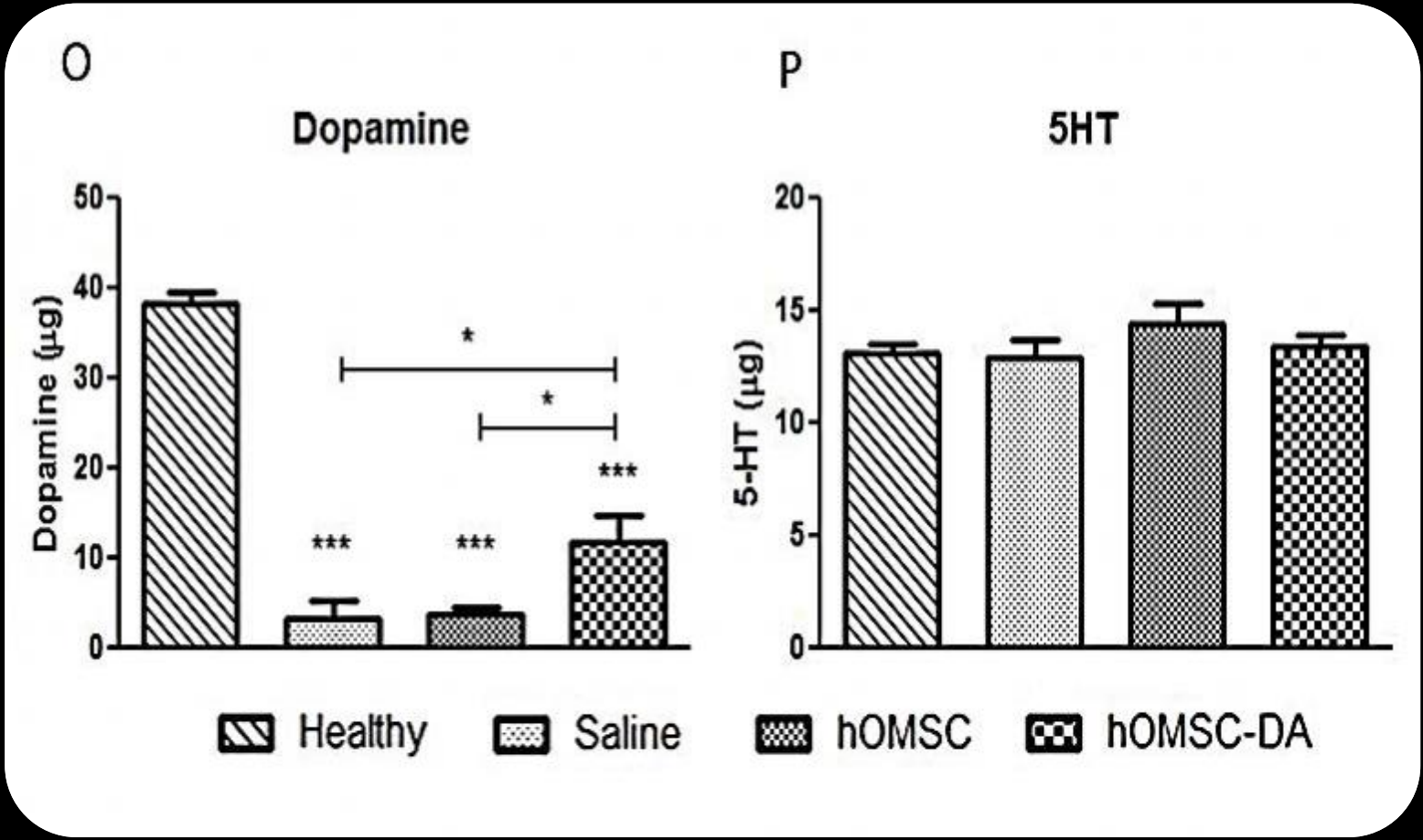

Summary

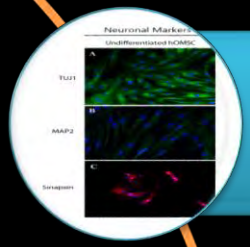

Oral Mucosa Stem Cells are neuronal prone stem cells

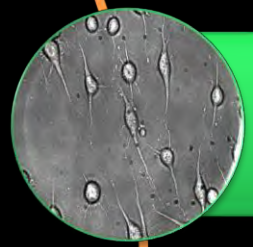

Phenotypical changes into Dopaminergic-like cells were evident after differentiation

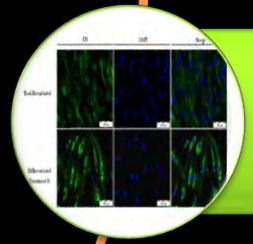

Transplanted cells significantly ameliorated a Parkinson's disease rat model

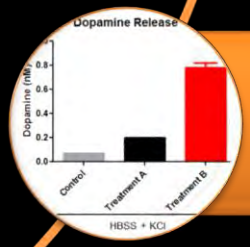

Differentiated Oral Mucosa Stem Cells maintained their phenotype *in vivo* during the experimental period

Challenges

- Symptomatic only
- Delivery
- Cell survival
- Side effects

Acknowledgements

- *Daniel Offen's Lab* , TAU
  - Javier Ganz
  - Tali Ben-Zur
  - Yael Barhum
- *Sandu Pitaru's Lab* TAU
  - Ina Arie
- Oral & Maxillofacial Department, Baruch Padeh Medical Center
  - Sammy Poor
  - Shareef Araidy